

Database of questions for the Medical-Dental Final Examination  
(LDEK)  
Part 1  
Orthodontics

Modified 18.12.2023

Pytanie nr 1

Indicate **the false** statement concerning the prophylaxis of finger sucking:

- A. in the case of prolonged finger sucking calming pacifiers should be used.
- B. there are two types of calming pacifiers.
- C. in children with primary dentition and older children the elimination of finger sucking should be based on diet changing and solid food introduction.
- D. in small children sucking habits can be eliminated through reeducation and tongue exercises.
- E. in infants and small children cuffs limiting the movements in the cubital joint can be used.

Pytanie nr 2

The extrinsic factors inducing dental and occlusal defects in fetal period **do not** include:

- 1) external injuries;
- 2) vitamin A deficiency;
- 3) impaired secretion of the anterior pituitary gland;
- 4) impaired parathyroid hormone secretion;
- 5) dorsal position of the mother during sleep in the first trimester of pregnancy.

The correct answer is:

- A. 1,2,3.
- B. 2,3,4.
- C. 1,2,5.
- D. 4,5.
- E. 3,5.

### Pytanie nr 3

The first physiological increase in the vertical occlusal dimension occurs as a consequence of:

- 1) eruption of the first deciduous molars;
- 2) eruption of the first permanent molars;
- 3) growth of the alveolar processes;
- 4) growth of the mandibular body;
- 5) growth of the mandibular ramus.

The correct answer is:

- A.** 1,3.
- B.** 2,3.
- C.** 1,3,5.
- D.** 2,3,4.
- E.** 2,3,5.

### Pytanie nr 4

When does atrophy of the pharyngeal tonsil take place in children?

- A.** approximately at the age of 10 years.
- B.** approximately at the age of 11 years.
- C.** approximately at the age of 12 years.
- D.** approximately at the age of 13 years.
- E.** approximately at the age of 14 years.

### Pytanie nr 5

What is the name of a unique feature of wires made of nickel-titanium alloys consisting in the fact that these arches at low temperatures can be freely formed and after heating return to their original shape:

- A.** pseudo-elasticity.
- B.** superelasticity.
- C.** stiffness.

D. shape memory.

E. temperature memory.

#### Pytanie nr 6

Indicate the true statements concerning the headcap with chin cap:

- 1) it is an active extraoral apparatus;
- 2) it is a passive extraoral apparatus;
- 3) is used for treatment of mesiocclusions, mandibular prognathism and open bites;
- 4) can be used as the only method of treatment or as a supportive treatment;
- 5) can be used as the only method of treatment, as a supportive treatment or in retention procedures;
- 6) can be used only in milk and mixed dentition.

The correct answer is:

A. 1,3,5,6.

B. 1,3,4,6.

C. 2,3,5.

D. 2,3,5,6.

E. 1,3,5.

#### Pytanie nr 7

Indicate the true statements concerning the tongue rest position in the mouth:

- 1) rest position of the tongue does not affect dental malocclusion formation;
- 2) anterior rest positioning of the tongue between the upper and lower dental arches may cause anterior or posterior open bite;
- 3) low tongue positioning promotes class III malocclusion;
- 4) low tongue positioning promotes crossbite;
- 5) high rest positioning of the tongue promotes scissor bite formation.

The correct answer is:

A. only 1.

B. 2,3.

C. 3,5.

D. 3,4,5.

E. 2,3,4,5.

### Pytanie nr 8

Indicate the true statement concerning orthodontic brackets:

- A.** slot width for the archwire is 0.028' and slot depth 0.022'.
- B.** slot width for the archwire is 0.028' and slot depth 0.018' or 0.022'.
- C.** slot for the archwire is wide in the transversal dimension and its width is 0.018' or 0.022' whereas the depth is 0.028'.
- D.** slot for the archwire is narrow and its width is 0.018' whereas the depth is 0.022'.
- E.** every bracket is of different width and depth depending on an individual tooth.

### Pytanie nr 9

Phase 2 of orthodontic treatment include:

- A.** sagittal alignment of teeth in the lateral segment.
- B.** midline correction.
- C.** control of spacing in the anterior region.
- D.** vertical alignment of the incisors (intrusion, extrusion).
- E.** all the above.

### Pytanie nr 10

The optimal strength for inclining larger teeth is:

- A.** 20-30 g.
- B.** 40-50 g.
- C.** 50-75 g.
- D.** 80-100 g.
- E.** 100-150 g.

### Pytanie nr 11

Ectopia is defined as:

- A. teeth displacement beyond the oral cavity.
- B. location of a tooth bud outside of the alveolar bone.
- C. teeth malposition in the alveolar bone.
- D. teeth transposition.
- E. retraction of an upper tooth above and a lower tooth below the occlusal plane.

**Pytanie nr 12**

The description "lip and palate total cleft (until the incisive foramen) bilateral" applies to the classification:

- A. according to Kernahan and Stark.
- B. according to Bardach, Perczyńska-Partyka.
- C. according to Veau.
- D. according to Hasun.
- E. according to Masztalerz.

**Pytanie nr 13**

The stage of bone remodeling, in which the elimination of vitreous masses and the resorption of the alveolar bone in the compression zone occur, is called:

- A. early stage.
- B. transient stage.
- C. stabilization stage.
- D. late stage.
- E. elimination stage.

**Pytanie nr 14**

Indicate the true statements concerning Andrew's keys of normal occlusion:

- 1) mesial palatal cusp of the first permanent upper molar is situated in the medial fissure of the first permanent lower molar;
- 2) in the normal occlusion the gingival part of each tooth long axis is mesially inclined in comparison to the part of the crown directed towards the occlusal plane;

- 3) torque of the crowns of incisors: the incisal edge of upper incisors is situated lingually relative to the cervical part of the crowns of these teeth;
- 4) molars and premolars rotated around the long axis take up more space in the dental arch;
- 5) rotated incisors take up less space in the arch in comparison to their normal position.
- The correct answer is:

- A. 1,2,4,5.
- B. 1,4,5.
- C. 1,2,3.
- D. 4,5.
- E. all the above.

#### Pytanie nr 15

How much time does the stabilization of elastic fibers in periodontium take after the completion of the active phase of orthodontic treatment?

- A. 10 weeks.
- B. 4 months.
- C. 6 months.
- D. 8 months.
- E. 12 months.

#### Pytanie nr 16

Nickel-titanium alloy:

- A. may assume two types of crystal structures: martensite - in low temperatures and austenite - in high temperatures.
- B. may assume two types of crystal structures: martensite - in high temperatures and austenite - in low temperatures.
- C. exhibits shape memory.
- D. true answers are A and C.
- E. true answers are B and C.

### Pytanie nr 17

The correct function of stomatognathic muscles influences:

- 1) skeletal development of the stomatognathic system;
- 2) correct relation of the maxilla and the mandible;
- 3) size of teeth;
- 4) harmonic dental arch shape;
- 5) size of the tongue.

The correct answer is:

- A.** 1,2,4.
- B.** 2,3,4.
- C.** 1,3,4.
- D.** 1,4,5.
- E.** 4, 5.

### Pytanie nr 18

At which stage of the child's life should solid food be introduced in order to secure a proper development of the stomatognathic system?

- A.** from 3rd month of age.
- B.** after the eruption of primary incisors.
- C.** after the eruption of canines.
- D.** after the eruption of primary molars.
- E.** during the exchange of dentition from the primary to the permanent one.

### Pytanie nr 19

The mesial position of the canine in relation to the line connecting the distal point of the incisive papilla and perpendicular to the palatal line of the palatal suture is evidence of:

- A.** primary crowding.
- B.** secondary crowding.
- C.** bilateral mesialization of lateral teeth.

**D.** true answers are A and B.

**E.** true answers are B and C.

#### Pytanie nr 20

The sucking reflex is a physiological activity at birth, but it may lead to malocclusion if it is retained too long. The sucking reflex should normally disappear by:

**A.** 6 month of life.

**B.** 12 month of life.

**C.** 18 month of life.

**D.** 30 month of life.

**E.** 4 year of life.

#### Pytanie nr 21

The junction between the two lateral halves of the mandible is fused by:

**A.** 1 year of age.

**B.** 2 years of age.

**C.** 3 years of age.

**D.** 5 years of age.

**E.** 8 years of age.

#### Pytanie nr 22

Which of the following concerning ectodermal dysplasia are true?

- 1) its characteristic features include malformation of middle and lower facial part. hypoplasia of the alveolar bone because of multiple hypodontia;
- 2) its characteristic features include multiple impacted teeth and supernumerary teeth;
- 3) its characteristic features include lack of many tooth buds, late eruption, small and conical teeth;
- 4) in group A according to Freire-Maia and Pinheiro minimum 3 signs must be diagnosed: hair disorder, teeth disorder, nail dysplasia, sweating disorders;
- 5) in group A according to Freire-Maia and Pinheiro minimum 2 signs must be diagnosed: hair disorder, teeth disorder, nail dysplasia, sweating disorders;
- 6) another name for the syndrome is mutual dysostosis.

The correct answer is:



**A.** 1,3,5.

**B.** 3,5.

**C.** 1,2,3,4.

**D.** 1,3,4.

**E.** 1,5,6.

### Pytanie nr 23

Indicate the true statement concerning the characteristics of stainless steel archwires:

**A.** they are characterized by great stiffness, small flexibility, resistance to sharper bends.

**B.** they are characterized by great stiffness, small plasticity, resistance to sharper bends.

**C.** produce great friction in archwire-slot pairs.

**D.** cannot be soldered and welded.

**E.** none of the above.

### Pytanie nr 24

Which craniofacial syndrome are the following symptoms characteristic of:

- impeded development of TMJ, maxilla and zygomatic bone,
- impeded development of mandibular corpus and a frequently observed lack of the mandibular ramus,
- asymmetric position of the eyes,
- primary palate cleft?

**A.** Goldenhar syndrome.

**B.** auricular mandibular dysostosis.

**C.** acrocephalosyndactylia.

**D.** hereditary craniofacial dysostosis.

**E.** Francois-Haustrat syndrome.

### Pytanie nr 25

Indicate the effect caused by Herbst appliance:

- A.** distalization of teeth in the maxilla.
- B.** mesialization of teeth in the mandible.
- C.** passive eruption of the lower molar teeth.
- D.** forward positioning of the mandible.
- E.** all the above.

**Pytanie nr 26**

Indicate the true statements regarding beta titanium archwires:

- 1) are used for early torque control and leveling the curve of Spee;
- 2) are used for elimination of small crowding and early derotation of teeth;
- 3) are used for leveling and aligning teeth in the final phase;
- 4) are not indicated for the formation of loops and segmental archwires;
- 5) are used as intrusion, retraction arches.

The correct answer is:

- A.** 1,3,5.
- B.** 1,2,3,5.
- C.** 2,5.
- D.** 2,4.
- E.** only 4.

**Pytanie nr 27**

At which stage of the child's life is the treatment with a face mask the most beneficial?

- A.** full primary dentition.
- B.** early mixed dentition.
- C.** late mixed dentition.
- D.** late permanent dentition.
- E.** after the growth spurt.

**Pytanie nr 28**

High rigidity, low elasticity and low wire-bracket friction are the features of:

- A. stainless steel wire.
- B. cobalt-chromium wire.
- C. M-NiTi wire.
- D. A-NiTi wire.
- E. TMA wire.

**Pytanie nr 29**

What is the minimal force per site recommended in the case of orthopedic movements using a Headgear appliance?

- A. 50 g.
- B. 350 g.
- C. 400 g.
- D. 450 g.
- E. 800 g.

**Pytanie nr 30**

What is the value of the intercanine distance at the age of over 11-13 years?

- A. 20-22 mm.
- B. 22-24 mm.
- C. 24-26 mm.
- D. 26-28 mm.
- E. 28-30 mm.

**Pytanie nr 31**

According to Broadbent the growth of the face is:

- A. forward.
- B. forward and upward.

- C. forward and downward.
- D. backward and downward.
- E. backward.

Pytanie nr 32

Which of the following features of the stainless steel wire and beta-titanium wire is common for both alloys?

- A. level of stiffness.
- B. possibilities of soldering and welding.
- C. nickel content.
- D. generating of weak forces.
- E. range of plasticity.

Pytanie nr 33

Which malocclusion **cannot be** treated using a lower acrylic inclined bite plane?

- A. total mesiocclusion.
- B. partial mesiocclusion.
- C. pseudo mesiocclusion.
- D. total crossbite.
- E. partial anterior crossbite.

Pytanie nr 34

The period until the 7th week of fetal life is crucial for the correct fusion of:

- A. nasal processes.
- B. upper lip.
- C. primary palate.
- D. all the above.

E. none of the above.

Pytanie nr 35

Chose the **false** sentence describing impressions taken in infants with a cleft palate:

A. utilization of alginate.

B. infant is always placed flat for better evaluation of the cleft extent.

C. alginate should be distributed on a spoon without excess.

D. it is recommended to put a piece of gauze in the middle of the spoon.

E. impression taken without gauze may lead to alginate wedge formation and the necessity to remove it through the nose.

Pytanie nr 36

Which statements describe the correct maxillary bone growth (primary displacement)?

1) maxilla moves downwards and forwards;

2) maxilla moves downwards and backwards;

3) it is mild clockwise rotation;

4) it is mild counterclockwise rotation;

5) it depends on the cranial growth.

The correct answer is:

A. 1,3.

B. 2,4.

C. 1,4,5.

D. 2,3,5.

E. 2,3.

Pytanie nr 37

Indicate the true statements concerning distocclusions:

1) common characteristic is a posterior relation of the lower dental arch towards the upper dental arch;

2) common characteristic is increased overbite;

3) patient's profile is not always changed;

4) they are assessed in relation to the sagittal plane;

5) they are the most common malocclusions, as they constitute about 45% of all malocclusions.

The correct answer is:

- A. 1,3,5.
- B. 1,3,4,5.
- C. 1,2,3.
- D. 1,5.
- E. all the above.

**Pytanie nr 38**

Which of the following orthodontic alloys has the lowest flexibility?

- A. chromium-cobalt alloy.
- B. stainless steel.
- C. beta-titanium (TMA).
- D. nickel-titanium alloy.
- E. nickel-titanium-copper alloy.

**Pytanie nr 39**

A 7-year-old patient comes to the clinic. Parents are concerned about diastema between upper central incisors. During examination you see; diastema, erupted teeth 16, 11, 21, 26, 36, 32, 31, 41, 42, 46 and the presence of teeth 55, 54, 53, 52, 62, 63, 64, 65, 75, 74, 73, 83, 84, 85, Angle class I bilaterally, upper lip frenulum correctly placed. Which is the correct treatment?

- A. fixed upper appliance to close the diastema.
- B. composite widening of teeth 11 and 21 to close the diastema.
- C. functional appliance to close the diastema.
- D. frenulectomy; because despite the correct attachment, the upper lip frenulum always causes diastema.
- E. observation; this situation is physiological.

**Pytanie nr 40**

A 14-year-old child came to the doctor's office. During examination the following were

diagnosed: mixed dentition - erupted permanent teeth apart from 13 and the presence of primary tooth 53. The parents state that tooth 23 erupted approximately 2 years ago. What action should be recommended?

- A.** diagnostics in order to plan treatment: orthopantomogram.
- B.** diagnostics in order to plan treatment: magnetic resonance.
- C.** urgent extraction of tooth 53.
- D.** only massages of the gingiva in the region of tooth 53.
- E.** observation because the described state is physiological and does not require treatment.

**Pytanie nr 41**

The morphological posterior position of the mandible is characterized by:

- 1) inhibition of anterior mandibular growth;
- 2) elongation of the mandibular ramus;
- 3) elongation of the lower facial segment;
- 4) retrusion of the chin beyond the biometrical field;
- 5) shortened mandibular corpus.

The correct answer is:

- A.** 1,2.
- B.** 1,2,3.
- C.** 1,3,4,5.
- D.** 2,3,4,5.
- E.** all the above.

**Pytanie nr 42**

Prolonged treatment with the chin cup appliance may lead to:

- A.** anterior displacement of the articular disc.
- B.** posterior displacement of the articular disc.
- C.** anterior maxillary growth impairment.
- D.** transversal maxillary growth deficiency.

**E.** none of the above.

**Pytanie nr 43**

Which of the following is an indication for the recommendation of Skaloud exercise for a child?

**A.** weak muscle tone of the lips and cheeks.

**B.** nasal breathing.

**C.** mesiocclusion malocclusions.

**D.** distocclusion malocclusions.

**E.** myo-arthropathies.

**Pytanie nr 44**

Which malocclusion occurs most frequently in Down syndrome?

**A.** full class II.

**B.** partial class II.

**C.** scissor bite.

**D.** class III.

**E.** deep bite.

**Pytanie nr 45**

Which type of plaster is used for embedding models in articulators and preparing bases of models?

**A.** impression plaster.

**B.** model plaster.

**C.** die cast plaster.

**D.** synthetic plaster.

**E.** calcined (burned) plaster.

**Pytanie nr 46**



Which features are characteristic of steel archwires, especially stainless steel (SS), used in orthodontics?

- 1) can be soldered and welded;
- 2) tooth movement generates considerable friction;
- 3) their features cannot be changed by heat treating;
- 4) are easy to form and bend;
- 5) can be formed but can break in sharp bends.

The correct answer is:

**A.** 1,2,3,5.

**B.** 1,2,4.

**C.** 2,3,5.

**D.** 1,4.

**E.** all the above.

#### Pytanie nr 47

Superelastic nickel titanium wires **should not** be used:

- 1) as the initial wires at significant crowding;
- 2) as the initial wires at small or medium crowding;
- 3) when closing extraction spaces with laceback ligatures - the teeth may be tilted towards postextraction spaces;
- 4) when using open springs for getting space for impacted teeth;
- 5) during levelling and aligning phase in the initial stages of the treatment.

The correct answer is:

**A.** 1,2,3,5.

**B.** 1,2,5.

**C.** 3,4.

**D.** 2,5.

**E.** all the above.

#### Pytanie nr 48

Which malocclusion has the following description: 2nd class on canines, 1st class of Angle, increased face angle F (according to Schwarz), SNB angle in the norm, pogonion point in the biometric field?

**A.** pseudo mesiocclusion.

- B.** pseudo distocclusion.
- C.** partial distocclusion.
- D.** morphologically distal position of the mandible.
- E.** partial mesiocclusion.

Pytanie nr **49**

In children with Pierre-Robin syndrome, in order to enable the correct growth of the stomatognathic system, one should apply:

- A.** natural feeding.
- B.** Dreyfus bottle.
- C.** Müller-Balters bottle.
- D.** Duenn's bottle.
- E.** any of the above.

Pytanie nr **50**

Disorders, in which congenital macroglossia may occur, include:

- 1) muscle hypertrophy;
- 2) glandular hyperplasia;
- 3) angioma;
- 4) hyperthyroidism;
- 5) lymphoma.

The correct answer is:

- A.** 1,2.
- B.** 1,2,3.
- C.** 1,2,3,4.
- D.** 1,2,3,5.
- E.** all the above.

Pytanie nr **51**

Which of the following statements correctly describes stage D in the development of

single root permanent teeth by Demirijan?

- A. mineralization sites merge, forming dental nodules.
- B. mineralization of the upper level of the crypt begins.
- C. crown formation is completed, up to the enamel-cement border.
- D. enamel formation on the chewing surface is completed.
- E. root canal walls have a parallel course.

Pytanie nr **52**

The ideal timing for functional treatment according to Baccetti is:

- A. CVMS I.
- B. CVMS II.
- C. CVMS III.
- D. CVMS IV.
- E. CVMS V.

Pytanie nr **53**

Which of the following is characteristic of the total open bite?

- A. speech impediment, which is always present.
- B. lip tension.
- C. preserved extraoral features.
- D. normal mastication.
- E. shortened lower lip.

Pytanie nr **54**

Indicate the true statements about trainers:

- 1) they are standard appliances made of flexible materials;
- 2) they are standard appliances made of rigid acrylic;
- 3) they are contraindicated if there are obstacles in the respiratory tract, e.g. allergic swelling of the mucosa;
- 4) a significant disadvantage of these appliances is greater discomfort than in the case

of an individual functional apparatus;

5) a significant advantage of these appliances is greater comfort than in the case of an individual functional appliance.

The correct answer is:

**A.** 1,4.

**B.** 1,3,4.

**C.** 1,3,5.

**D.** 2,3,5.

**E.** 2,4.

#### Pytanie nr 55

Which of the following types of plaster are used in orthodontics?

1) plaster used for taking impressions- type 1;

2) plaster used for making models- type 2;

3) plaster used for molding- type 3;

4) plaster used for molding with increased resistance and low expansion - type 4;

5) synthetic plaster - type 4.

The correct answer is:

**A.** 1,2,3,4.

**B.** 2,3,5.

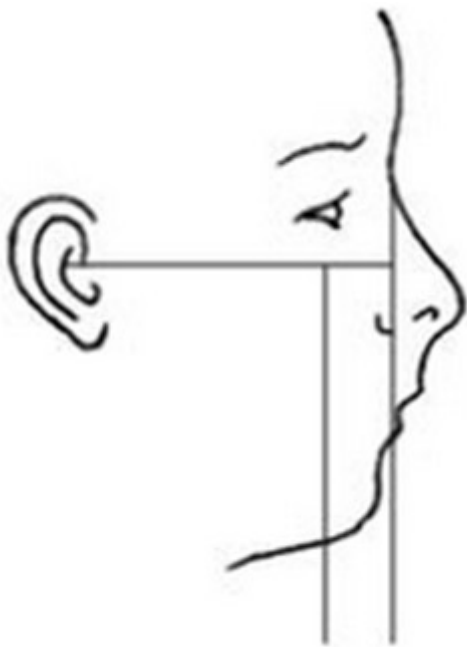
**C.** 2,3,4.

**D.** 1,3.

**E.** all the above.

#### Pytanie nr 56

Describe the presented type of profile according to Izard and Schwarz:



- A. facial profile mesofrontal, maxillary profile straight.
- B. facial profile transfrontal, maxillary profile straight.
- C. facial profile transfrontal, maxillary profile oblique distally.
- D. facial profile cisfrontal, maxillary profile oblique distally.
- E. facial profile cisfrontal, maxillary profile oblique mesially.

Pytanie nr **57**

Which characteristic features conclude the final termination of facial skeleton/viscerocranium growth?

- 1) transformation of the cartilage on the mandibular condyle into bone (ossification of the growth centre);
- 2) transformation of the nasal cartilage into bone (ossification of the growth centre);
- 3) final ossification of the temporo-zygomatic suture;
- 4) final ossification of the palatal suture;
- 5) eruption of third permanent molars;
- 6) eruption of lower third permanent molars.

The correct answer is:

- A. 1,3,5.
- B. 1,4,5.
- C. 1,4,6.
- D. 2,4,5.
- E. 2,4,6.

Pytanie nr 58

Which of the following develops from Meckel's cartilage?

- A. stapes and incus.
- B. stapes and malleus.
- C. malleus and incus.
- D. wings of the sphenoid bone.
- E. stylomandibular ligament.

Pytanie nr 59

An extrusive tooth movement results in:

- A. parallel tooth displacement.
- B. tooth displacement along the long axis of the tooth toward the occlusal plane.
- C. tooth displacement along the long axis of the tooth toward the alveolus.
- D. tooth rotation around its long axis.
- E. root apex displacement in relation to the crown.

Pytanie nr 60

Indicate the true statements concerning the persistent tooth:

- 1) another name for persistent tooth is *persistentio dentis*;
- 2) another name for persistent tooth is *retentio dentis*;
- 3) it is a primary tooth still present in the oral cavity after its physiological exfoliation time;
- 4) it is a permanent tooth still present in the oral cavity after its physiological exfoliation time;
- 5) most frequently observed persistent teeth are lower canines and second upper molars;
- 6) most frequently observed persistent teeth are primary upper canines and second lower molars;
- 7) tooth persistence may be caused by a missing primary tooth bud or its pathological position;
- 8) tooth persistence may be caused by a permanent tooth bud or its pathological position.

The correct answer is:

**A.** 1,3,5,7.

**B.** 2,4,6,8.

**C.** 1,4,6,7.

**D.** 1,3,6,8.

**E.** 2,3,5,7.

**Pytanie nr 61**

What is the average palate height according to Korkhaus?

**A.** 30%.

**B.** 37%.

**C.** 42%.

**D.** 48%.

**E.** 52%.

**Pytanie nr 62**

Flattened upper lip, deepened nasolabial fold, prominent lower lip and chin displacement towards the malocclusion side are present in:

**A.** partial lateral crossbite.

**B.** mandibular deviation.

**C.** partial anterior crossbite.

**D.** total crossbite.

**E.** B and D are true.

**Pytanie nr 63**

The second physiological mandibular advancement is the result of:

**A.** intensive growth of the mandible during fetal development.

**B.** intensive growth of the mandible during the first 4 months of life.

**C.** attrition of dental cusps in deciduous dentition and mandibular advancement during the stage preceding the transition from deciduous to permanent dentition.

**D.** late mandibular growth.

**E.** eruption of the permanent second molars.

**Pytanie nr 64**

Indicate the true statements regarding the cleidocranial dysplasia:

1) is classified as a symmetrical disturbance of I and II branchial arch;

2) numerous supernumerary teeth are present together with teeth in retention;

3) skull ossification is abnormal;

4) facial morphology is normal.

The correct answer is:

**A.** 1,2,3.

**B.** 2,3.

**C.** 2,4.

**D.** 1,3.

**E.** 1,2,4.

**Pytanie nr 65**

Indicate the true statement concerning Izard Index:

**A.** Izard Index determines the correlation between the lower arch width and the upper facial width.

**B.** the index value should be 20.

**C.** acceptable discrepancy is +/- 15.

**D.** Izard Index is used regardless of age and type of dentition.

**E.** none of the above.

**Pytanie nr 66**

Indicate the true statements regarding the development of speech function in children:

1) the articulation must be closely synchronized with the breath;

2) first, the child pronounces lip consonants (m, p, b), formed by the anterior part of the tongue (t, d, l, n) and posterior part of the tongue (k, g);



- 3) first, the child pronounces hissing consonants (s, z, c, dz);  
4) buzzing consonants appear last (ʃ, tʃ, ʒ, dz, dʒ);  
5) pronunciation is the motor part of speech, which means that deviations in previous functions, e.g. swallowing - may be the basis for speech irregularities.

The correct answer is:

- A. 2,4.
- B. 3,4.
- C. 1,3,4,5.
- D. 1,2,4,5.
- E. all of the above.

Pytanie nr **67**

Stage CVM-2 according to Hassel and Farman classification is also referred to as:

- A. initial stage.
- B. acceleration stage.
- C. transition stage.
- D. deceleration stage.
- E. maturation stage.

Pytanie nr **68**

Rees analysis enables evaluation of:

- A. correlation of the length of the dental arch with the sum of the width of the incisors.
- B. occlusal plane.
- C. relation between the apical base span and the dental arch length - an analysis of the apical base.
- D. relationship between the height of the palate and the width of the dental arch.
- E. bilateral mesialisation of lateral teeth.

Pytanie nr **69**

Slow Palatal Expansion (SPE) device is activated at the rate of:

A. 0.1-0.3 mm / day.

B. 0.2-0.4 mm / day.

C. 0.3-0.5 mm / day.

D. 1.0 mm / week.

E. 2.0 mm / week.

#### Pytanie nr 70

Which of the following correctly describe somatic swallowing in patients over the age of four?

1) may contribute to class III malocclusion;

2) may contribute to open bite, class II and cross bite;

3) this dysfunction consists in swallowing in disclusion while the tongue, placed forward, lies between the upper and lower gingiva;

4) mandible is stabilized by facial muscles;

5) mandible is stabilized by mandible elevators;

6) it's physiological.

The correct answer is:

A. 1,3,4.

B. 2,3,4.

C. 1,3,5.

D. 5,6.

E. 2,3,5.

#### Pytanie nr 71

In children as many as 80% of disturbances concerning jaws, occlusion and teeth are caused by local exogenic factors. An example of such a factor **is not**:

A. dysfunction.

B. parafunction.

C. hormonal disorder.

D. consequence of caries.

**E.** trauma.

**Pytanie nr 72**

The physiognomic face is located between:

- A.** trichion and gnathion.
- B.** trichion and menton.
- C.** ophryon and pogonion.
- D.** ophryon and gnathion.
- E.** nasion and gnathion.

**Pytanie nr 73**

At birth children reveal:

- A.** embryonal prognathism.
- B.** fetal progenia.
- C.** pseudo-distoclusion.
- D.** morphological retrogenia.
- E.** physiological retrogenia.

**Pytanie nr 74**

The upper part of the first pharyngeal arch gives rise to:

- A.** maxillary process.
- B.** mandibular process.
- C.** main part of the tongue.
- D.** malleus.
- E.** incus.

**Pytanie nr 75**

Which of the following cephalometric measurements allows to evaluate the anteroposterior position of incisors?

- A. SNA angle.
- B. SNB angle.
- C. ANB angle.
- D. interincisal angle.
- E.  $\underline{1}$ -NA angle.

Pytanie nr 76

Which stage of development is the ideal time to begin functional treatment ?

- A. CVMS I.
- B. CVMS II.
- C. CVMS III.
- D. CVMS IV.
- E. CVMS V.

Pytanie nr 77

A peak of the pubertal growth spurt according to Björk occurs if on the hand-wrist radiograph:

- A. epiphysis and diaphysis of the middle phalanx of the middle finger are equal in width.
- B. proximal phalanx of the second digit and its epiphysis are equal in width.
- C. fusion of the epiphysis and the diaphysis of the radius is seen.
- D. sides of the epiphysis of the middle phalanx of the 3<sup>rd</sup> finger caps its metaphysis.
- E. fusion between the epiphysis and the diaphysis of the middle phalanx of the middle finger takes place.

Pytanie nr 78

The value of the nasal-maxillary index by Masztalerz is:

- A. 78 in boys and 80 in girls.
- B. 80 in boys and 78 in girls.

**C.** 80 both in boys and in girls.

**D.** 78 both in boys and in girls.

**E.** 70 in boys and 60 in girls.

**Pytanie nr 79**

Delayed eruption or retention of permanent teeth most often applies to:

- 1) medial upper incisors;
- 2) second upper premolars;
- 3) lateral lower incisors;
- 4) first permanent molars;
- 5) canines.

The correct answer is:

**A.** 1,5.

**B.** 2,3.

**C.** 2,5.

**D.** 3,4.

**E.** 1,3.

**Pytanie nr 80**

Which of the following radiographs enables the assessment of a skeletal age?

**A.** orthopantomogram.

**B.** functional image by Schüller.

**C.** lateral cephalogram.

**D.** occlusal projection of the maxilla.

**E.** projection by Waters.

**Pytanie nr 81**

What are the advantages of the Herbst appliance in comparison with functional appliances?

**A.** works 8 hours/day and treatment time is short (8-10 months).

- B.** works 16 hours/day and treatment time is short (5-7 months).
- C.** works 16 hours/day and treatment time is short (6-8 months).
- D.** works 24 hours/day and treatment time is short (3-5 months).
- E.** works 24 hours/day and treatment time is short (6-8 months).

**Pytanie nr 82**

Shortening of the mandibular corpus, underdeveloped chin, increased mandibular angle diagnosed on the lateral cephalogram suggest:

- A.** morphological retrogenia.
- B.** total distocclusion.
- C.** total open bite.
- D.** pseudodistocclusion.
- E.** morphological progenia.

**Pytanie nr 83**

The development of the hard palate is completed in:

- A.** 6<sup>th</sup> gestational week.
- B.** 7<sup>th</sup> gestational week.
- C.** 8<sup>th</sup> gestational week.
- D.** 12<sup>th</sup> gestational week.
- E.** 18<sup>th</sup> gestational week.

**Pytanie nr 84**

Indicate the true statement concerning transposition:

- A.** it is a displacement of teeth outside of the oral cavity.
- B.** it is a positioning of tooth bud outside of the alveolar proces.
- C.** it is a displacement of teeth with a change in their sequence.
- D.** it most frequently concerns lower canines.

E. C and D are true.

Pytanie nr 85

Parents of a 9-year-old patient worried about his incisors' shape. During examination one can see: between teeth 12 and 21 a small tooth of conical shape. What is the diagnosis?

A. dens invaginatus.

B. mesiodens.

C. dens concreti.

D. macrodens.

E. dentes confusi.

Pytanie nr 86

Short corpus and ramus of the mandible, significantly increased overjet, retrognathic profile and bilateral scissor bite are characteristic of:

A. retrogenia.

B. distocclusion.

C. pseudodistocclusion.

D. macrognathia.

E. microgenia.

Pytanie nr 87

Indicate the true statement concerning cleidocranial dysplasia:

A. it belongs to asymmetric disorders of I and II branchial arch.

B. mental growth is compromised.

C. numerous supernumerary and impacted teeth occur.

D. skull ossification is normal.

E. face morphology is normal.

Pytanie nr 88

Which of the following are a contraindication to the application of trainers?

- 1) polyps in the upper airways;
- 2) allergic swelling of the oral mucosa;
- 3) deviation of the nasal septum;
- 4) hypotonia of the orbicularis oris muscle;
- 5) latex allergy.

The correct answer is:

- A.** 1,2.
- B.** 1,2,5.
- C.** 3,4.
- D.** 2,4.
- E.** 1,2,3.

Pytanie nr 89

Which of the following types of anchorage will be used in the case of a symmetrical diastema closure?

- A.** stationary minimum anchorage.
- B.** stationary moderate anchorage.
- C.** maximum anchorage.
- D.** reciprocal anchorage.
- E.** extraoral anchorage.

Pytanie nr 90

The recommended force level for orthodontic changes during headgear therapy is:

- A.** 50-150 g per side.
- B.** 100-200 g per side.
- C.** 150-350 g per side.
- D.** 350-450 g per side.



E. 400-650 g per side.

### Pytanie nr 91

Distocclusions:

- 1) are characterized by increased overjet between incisors;
- 2) are characterized by the predominance of the protruding muscles over retruding;
- 3) characterized by the retraction and prominence of the lower lip;
- 4) are characterized by lisp in the case of a horizontal space over 3 mm;
- 5) constitute about 12-14% of all malocclusions.

The correct answer is:

A. 1,2.

B. 1,3.

C. 1,4.

D. 1,5.

E. 3,5.

### Pytanie nr 92

A patient aged 10 comes to the dental office - the parents express their concern about the shape of incisors in the maxilla. The examination of the maxillary anterior part revealed that the upper central incisor has an excessively wide crown with a vertical groove on the buccal surface with a depression on the incisal margin. The tooth 12 is absent, which was confirmed radiologically. Based on these findings one may diagnose:

A. persistent deciduous tooth.

B. mesiodens.

C. retained teeth.

D. microdontia.

E. tooth fusion.

### Pytanie nr 93

Hypodontia most frequently affects:

A. second upper premolars.

B. second lower premolars.

- C. third molars.
- D. upper lateral incisors.
- E. lower central incisors.

**Pytanie nr 94**

Which bone of the facial skeleton takes the longest time to grow?

- A. maxilla.
- B. mandible.
- C. zygomatic bone.
- D. palatine bone.
- E. vomer.

**Pytanie nr 95**

The first order bend is:

- A. artistik, sweep.
- B. tip back.
- C. inset, offset.
- D. bend enabling the control of bucco-lingual tooth axis.
- E. bend created to shorten extruded central incisors.

**Pytanie nr 96**

Worried parents of a 5-year-old child report that the child's mandible is growing, and there appeared spaces between the teeth. During examination you see: edge-to-edge relationship of the upper and lower incisors, palpable alveolar bone behind second milk molars, abrasion of milk teeth, spaces between lower canines and canines in the lower arch. What will you recommend?

- A. full orthodontic diagnosis, cephalogram x-ray to exclude prognathism.
- B. chin cap.
- C. Schöhherr plate for exercises.

**D.** Schwarz plate with posterior bite planes and Bertini screw.

**E.** only observation because the described situation is physiological.

**Pytanie nr 97**

Infraposition is:

**A.** position of a tooth or a group of teeth, which crosses above the occlusal plane.

**B.** position of a tooth or a group of teeth, which are beneath the occlusal plane.

**C.** position of a group of teeth characteristic of deepened overbite.

**D.** position of a group of teeth characteristic of deepened overjet.

**E.** true answers are A and C.

**Pytanie nr 98**

The physiological face is located between:

**A.** superciliary arches and the border of the mandibular corpus.

**B.** ophryon and gnathion points.

**C.** nasion and gnathion points.

**D.** trichion and gnathion points.

**E.** none of the above.

**Pytanie nr 99**

Which of the following doesn't form from the first pharyngeal arch?

**A.** maxillary process.

**B.** styloid process.

**C.** anterior belly of the digastric muscle.

**D.** incus.

**E.** malleus.

**Pytanie nr 100**

The Simon plane goes through:

- A. Nasion point and is perpendicular to Frankfurt and sagittal planes.
- B. Glabella point and is perpendicular to Frankfurt and sagittal planes.
- C. Orbitale point and is perpendicular to Camper plane.
- D. Orbitale point and is perpendicular to Frankfurt and sagittal planes.
- E. Nasion point and is perpendicular to Camper plane.

Pytanie nr **101**

The optimal orthodontic force used for intrusion is:

- A. 15-25 g.
- B. 30-50 g.
- C. 50-75 g.
- D. 100-150 g.
- E. 150-300 g.

Pytanie nr **102**

Andrews' keys to normal occlusion **do not** include:

- A. molar relationship: the distal vestibular cusp of the first upper permanent molar occludes with the mesial surface of the mesial vestibular cusp of the first lower permanent molar.
- B. crown inclination.
- C. torque.
- D. fact that rotated molars and premolars take up more space in the arch.
- E. flat curve of Spee: its depth shouldn't exceed 1.5 mm.

Pytanie nr **103**

Andrew's Keys of Occlusion **do not** include:

- A. crown angulation 'tip'.

**B.** crown inclination 'torque'.

**C.** a state in which rotated alongside their long axis molars or premolars occupy more space in the dental arch and rotated incisors occupy less space than in the normal position.

**D.** interproximal contact - contact points between adjacent teeth should be kept.

**E.** deep curve of Spee, at least 2.5 mm.

**Pytanie nr 104**

Indicate the true statements concerning the delayed eruption of permanent teeth:

1) is described by the latin term *dentitio praecox*;

2) can be caused by general factors such as: heredity; hypofunction of the thyroid or the hypophysis, rickets;

3) can be caused by local factors such as: trauma and jaw cysts, dental disturbances regarding the tooth topography, supernumerary teeth and gingival fibromatosis;

4) it is diagnosed when permanent teeth erupt in the oral cavity within 3 months after the supposed time of their eruption;

5) it is diagnosed when permanent teeth erupt in the oral cavity within a year or longer after the supposed time of their eruption.

The correct answer is:

**A.** 1,2,3,4.

**B.** 1,2,3,5.

**C.** 2,3.

**D.** 2,3,4.

**E.** 2,3,5.

**Pytanie nr 105**

Indicate the true statement regarding the clinical application of various functional regulators by Fränkl:

**A.** Fr I - treatment of distocclusion with retroclination of the upper incisors or partial deep bite.

**B.** Fr II - treatment of mesiocclusion.

**C.** Fr IV - treatment of bimaxillary protrusion.

D. Fr III - treatment of distocclusion with proclination of incisors.

E. Fr III - treatment of open bite.

Pytanie nr **106**

The center of gravity for single root teeth is around:

A. 1/3 of the tooth root length from its neck.

B. 1/2 of the tooth root length from its neck.

C. tooth cervix.

D. 1/3 tooth crown.

E. 1/2 tooth crown.

Pytanie nr **107**

Which of the following muscles **does not** originate from the first branchial arch?

A. orbicularis oris.

B. masseter.

C. lateral pterygoid.

D. temporalis.

E. mylohyoid.

Pytanie nr **108**

The impaction of which permanent tooth is most often observed after a premature loss of deciduous teeth as a result of spontaneous migration of teeth and insufficient space in the dental arch?

1) upper canine;

2) lower canine;

3) first lower premolar tooth;

4) second lower premolar tooth;

5) first upper premolar tooth;

6) second upper premolar tooth.

The correct answer is:

A. 1,3,5.

**B.** 1,4.

**C.** 2,4.

**D.** 2,5,6.

**E.** 4,5,6.

**Pytanie nr 109**

The following indicators can be used to analyze the necessary space needed in support zones:

- 1) Moyers;
- 2) Tanaka and Johnston;
- 3) Dorschal;
- 4) Tonn;
- 5) Popovich.

The correct answer is:

**A.** 1,2,3.

**B.** 1,2,3,4.

**C.** 1,3,5.

**D.** 1,2,3,5.

**E.** all the above.

**Pytanie nr 110**

When the lip profile is correct the lip step according to Korkhaus should be:

**A.** positive.

**B.** increased, positive.

**C.** straight.

**D.** slightly negative.

**E.** increased, negative.

**Pytanie nr 111**

When during fetal development does the primary palate cleft occur?

- A. 1-3 week.
- B. 4-7 week.
- C. 7-12 week.
- D. 12-15 week.
- E. 12-20 week.

Pytanie nr **112**

Indicate the true statement concerning the reinclusion:

- A. it is a non-consecutive sequence of permanent teeth eruption.
- B. it is an alternative name for persistent teeth.
- C. it is a slow process in which the tooth moves away from the occlusal plane.
- D. it is a slow process of passive tooth eruption.
- E. it is a premature eruption of permanent teeth.

Pytanie nr **113**

Indicate the true statements concerning partial deep bite:

- 1) this malocclusion is characterized by excessive vertical growth of the anterior maxillary alveolar process and impeded growth of lateral maxillary and mandibular alveolar processes;
- 2) anterior mandibular movement till the tete-a-tete position of upper and lower incisors - excessive vertical space between occlusal surfaces of lateral teeth is formed;
- 3) two-step occlusal plane;
- 4) if the malocclusion is not complicated by distocclusion or scissor's bite - no change in extraoral features is present;
- 5) mandibular angle and intermaxillary angle are always decreased.

The correct answer is:

- A. all the above.
- B. 1,2,4.
- C. 2,3,4.
- D. 2,5.
- E. 2,3,5.



Pytanie nr 114

Pseudo Angle's class:

- A.** concerns deciduous teeth and evaluates bite disturbances in the antero-posterior plane.
- B.** is the degree of antero-posterior shift of the molar relationship expressed as the width of the premolar, e.g. 1/2 of class II.
- C.** occurs in the case of mesialization of the first permanent molar teeth as a result of a premature deciduous teeth loss.
- D.** describes the position of the upper dental arch in relation to the lower gingival arch in an infant.
- E.** none of the above.

Pytanie nr 115

Indicate the true statements about the active Schwartz plate:

- 1) is an active appliance;
- 2) by adding protrusion springs, the Schwartz plate becomes a mechanical-functional appliance;
- 3) in the plate, the centrally located Fischer screw is most often used, in the line of the first premolars;
- 4) the centrally located Fischer screw in the first molar line is most often used in the plate;
- 5) the pitch of the Fischer screw gives the widening of 1 mm;
- 6) patients are most often recommended to wear the device for at least 14 hours a day.

The correct answer is:

- A.** 1,3,6.
- B.** 1,4,6.
- C.** 1,2,3,6.
- D.** 1,2,5,6.
- E.** 2,5,6.

Pytanie nr 116

The height of the labial arch in the removable apparatus depends on the treatment plan. The closer the labial arch runs to the incisal edge, the larger:

- A. withdrawal of incisors.
- B. backwards inclination of incisors.
- C. forward incisal inclination.
- D. incisal rotation.
- E. distalization of canines.

Pytanie nr 117

Which factors support tooth extraction during orthodontic treatment?

- 1) deep bite;
- 2) proclined teeth;
- 3) mandible anteriorrotation;
- 4) mandible posteriorrotation;
- 5) decrease of the interincisal angle.

The correct answer is:

- A. 1,2,3.
- B. 1,3,5.
- C. 2,4,5.
- D. 1,4.
- E. 1,2,4,5.

Pytanie nr 118

Which index should be used for the assessment of the width of the dental arch?

- A. Little's.
- B. Masztalerz's.
- C. Moyers'.
- D. Droschl's.
- E. Pont's.

Pytanie nr 119

Find proper characteristics concerning the physiological lip position which are assessed

during extraoral examination:

- 1) approximately 2 mm of upper incisors' incisal edges should be displayed from underneath the upper lip at rest and on smiling;
- 2) at rest the lower lip should cover approximately 3/4 of the incisal part of the upper incisors' labial crown surface;
- 3) lip step according to Korkhaus should be positive;
- 4) the value of the nasolabial angle is approximately 109.8° and does not depend on age or gender;
- 5) in physiological conditions the subnasale-stomion distance makes 1/3 of the maxillary segment and the stomion-gnathion distance makes 2/3 of the maxillary segment height.

The correct answer is:

- A. 1,3.
- B. 1,4,5.
- C. 1,2,4,5.
- D. 2,3,5.
- E. 1,4.

**Pytanie nr 120**

Dystopic tooth is:

- A. incorrect position of teeth in the dental arch.
- B. positioning of teeth outside the dental arch.
- C. positioning of teeth outside the mouth.
- D. displacement of a tooth along the dental arch with the change of teeth sequence.
- E. retreat of an upper tooth above or a lower tooth below the occlusal plane.

**Pytanie nr 121**

The change in the inclination of the bracket slot in the mesio-distal direction in the straight wire technique enabled the introduction of:

- A. 1° offset bends.
- B. 1° inset bends.
- C. 2° angulation bends.

D. 2° torque bends.

E. 3° torque bends.

Pytanie nr 122

Fixed functional apparatuses **do not** include:

A. Herbst apparatus.

B. fixed bite surface.

C. Malu apparatus.

D. crown with a cast directional plane.

E. Nance appliance.

Pytanie nr 123

Partial open bite can result from:

- 1) infantile type of swallowing;
- 2) pacifier sucking;
- 3) vertical positioning of the sucked thumb;
- 4) nail biting;
- 5) habitual supporting of the chin with one's hand.

The correct answer is:

A. 1,2,4.

B. 2,3.

C. 3,4,5.

D. only 4.

E. all the above.

Pytanie nr 124

The screw that enables the jaw to expand in three directions is:

A. Fischer screw.

B. Bertoni's screw.

C. Przylipiak's screw.

D. Beutelspacher screw.

E. Hyrax.

Pytanie nr **125**

The free mouth opening range in adolescents and adults, measured from the edges of the upper incisors to the lower incisors, in the midline is:

A. 7-10 mm.

B. 10-14 mm.

C. 20-32 mm.

D. 40-52 mm.

E. 54-62 mm.

Pytanie nr **126**

Indicate the types of gypsum used in orthodontics:

A. impression plaster, model plaster, dental stone characterized by decreased strength and high expansion.

B. impression plaster, model plaster, synthetic.

C. model plaster, dental stone characterized by decreased strength and high expansion, dental stone characterized by increased strength and low expansion.

D. synthetic, model plaster, dental stone characterized by increased strength and low expansion.

E. model plaster, dental stone, synthetic.

Pytanie nr **127**

In Edgewise technique 5 phases of treatment can be distinguished according to Hasund:

1) levelling and aligning;

2) space closure and overjet correction;

3) retention;

4) finishing;

5) overbite control.

Indictate the correct sequence of these steps:

**A.** 1,2,3,4,5.

**B.** 1,3,2,5,4.

**C.** 1,5,2,4,3.

**D.** 4,1,5,2,3.

**E.** 1,5,4,2,3.

**Pytanie nr 128**

Which of the following describing postnatal masticatory system development is true?

- 1) child is born with physiological retrogenia;
- 2) breast feeding is the most important factor influencing the mandibular forward growth;
- 3) after the eruption of upper and lower incisors the overbite is deep;
- 4) the curve of Spee is lacking in full milk dentition;
- 5) in a 3-year-old child the upper arch is shaped like an ellipse and the lower arch like a parable;
- 6) in milk dentition development without spacing according to Baum, the mesial drift of the first lower molars occurs with falling out of the second milk teeth.

The correct answer is:

**A.** 1,2,3,4.

**B.** 1,3,4,5.

**C.** 1,2,4,5,6.

**D.** 3,4,6.

**E.** 1,3,4,6.

**Pytanie nr 129**

The dorsal position of child's head during sleep may lead to:

- A.** anterior displacement of the mandible and the tongue.
- B.** hypercontraction/activity of muscles responsible for moving the mandible forward which has an impact on the temporomandibular joint.
- C.** posterior displacement of the mandible and the tongue.
- D.** decrease in the range of the mandibular resting position, which causes the lips to part and an open bite to form.

E. C and D are true.

Pytanie nr 130

Indicate the true statements concerning the temporary increase in tooth mobility during orthodontic treatment:

- 1) usually leads to the loss of the affected tooth, even while maintaining perfect hygiene;
- 2) usually does not exceed the II or III degree of unstability;
- 3) first of all, the force acting on the tooth should be increased by raising the occlusion on the affected tooth with a composite material or glass-ionomer;
- 4) rarely, the cause of tooth pathological mobility may be tooth root resorption, especially in a replanted or ectopically erupted tooth;
- 5) each case of tooth pathological mobility should encourage radiological diagnostics.

The correct answer is:

A. 1,3,4.

B. 2,3,4,5.

C. 2,3,5.

D. 2,4,5.

E. 1,4,5.

Pytanie nr 131

Which of the following functional appliances is used for the treatment of an open bite?

A. Frankel - I appliance.

B. Frankel - II appliance.

C. Frankel - IV appliance.

D. Balter's bionator - standard type.

E. Balter's bionator - reverse type.

Pytanie nr 132

The Hass appliance is used to:

A. open the midpalatal suture.

B. expand the anterior region of the upper arch.

- C. maintain space after a premature loss of primary molars.
- D. reinforce the anchorage of upper molars.
- E. reinforce the anchorage of lower molars.

Pytanie nr 133

The center of resistance in multirrooted teeth is situated:

- A. in the infinity.
- B. in the area of force application.
- C. approx. at the level of the 1/3 of root length from the cervix.
- D. approx. at the level of the 1/3 of root length from the root apexes.
- E. in the furcation area.

Pytanie nr 134

Indicate the **false** statement concerning the straight wire technique:

- A. first order bend is in-set and off-set.
- B. third order bending is called tork.
- C. third order bends have been built into the bracket by inclination of the slot in the occlusal-gingival direction relative to its base or by inclination of the entire bracket.
- D. bending values of 1st, 2nd and 3rd order have been built into the bracket used in the straight-wire technique.
- E. first-order element is obtained by inclination of the slot in the relation to its base in the mesodistal direction.

Pytanie nr 135

Tonsillar hypertrophy can lead to the development of:

- A. crossbite.
- B. class III malocclusion.
- C. class II malocclusion.
- D. deep bite.



E. open bite.

Pytanie nr 136

A protruded lower lip and chin, shallow labial-mental fold are the features of:

- A. pseudo class III malocclusion.
- B. partial class III malocclusion.
- C. total class III malocclusion.
- D. mandibular prognathism.
- E. microgenia.

Pytanie nr 137

The applications of Schöhrer's vestibular plate include muscular exercises and:

- A. class III and open bite treatment.
- B. cross bite and class III treatment.
- C. class II and open bite treatment.
- D. class III treatment.
- E. class II treatment.

Pytanie nr 138

Pseudo class II malocclusion has:

- A. lower lip retrusion.
- B. upper lip protrusion.
- C. canine class I, Angle class II.
- D. increased SNB angle.
- E. decreased SNB angle.

Pytanie nr 139

Which of the following is the multisectioned screw used in lower plates in the cases of

incisor crowding when the tooth protrusion can be achieved?

- A. Przylipiak screw.
- B. Bertoni screw.
- C. Fisher screw.
- D. Beutelspacher screw.
- E. Schwarz screw.

**Pytanie nr 140**

The occlusal planes covering posterior upper teeth in Schwartz plate are utilized in the treatment of:

- 1) overbite;
- 2) cross bite;
- 3) open bite;
- 4) scissor bite.

The correct answer is:

- A. 1,2.
- B. only 2.
- C. 2,3.
- D. only 1.
- E. 1,2,4.

**Pytanie nr 141**

Which sentence describes WITS measurement (according to Jacobson)?

- A. angle between the lines NA and NB.
- B. projection of the points A and B on the occlusal plane OcP.
- C. proportional index describing relations between the middle and lower facial height.
- D. projection of the points A and B on the occlusal plane FOL.
- E. angle between the lines A-B and SpP.

**Pytanie nr 142**

Tonsil hypertrophy may result in:

- A. class III malocclusion.
- B. class II malocclusion.
- C. cross bite.
- D. deep bite.
- E. B and C are true.

Pytanie nr 143

The single, full vestibular screen is used for:

- 1) elimination of oral habits;
- 2) treatment of open bites;
- 3) treatment of scissor's bite;
- 4) treatment of distocclusions;
- 5) treatment of mesiocclusions.

The correct answer is:

- A. 1,2,3.
- B. 2,3,4.
- C. 1,2,4.
- D. 2,4,5.
- E. 3,4,5.

Pytanie nr 144

Which maxillo-occlusal disturbances are taken into consideration in relation to the horizontal plane?

- 1) partial anterior open bite;
- 2) total deep bite;
- 3) total mesiocclusion;
- 4) morphological distal position of the mandible;
- 5) pseudomesiocclusion.

The correct answer is:

- A. 1,2.
- B. 2,3.

C. 3,4.

D. 3,4,5.

E. 3,5.

Pytanie nr **145**

The individual acrylic vestibular plate by Hotz and Nord is used primarily in the treatment of:

A. distocclusion with retroclination of the upper incisors.

B. mesiocclusion.

C. partial lateral crossbite.

D. scissor's bite.

E. distocclusion with proclination of the upper incisors.

Pytanie nr **146**

Which malocclusion is the most frequent?

A. Class II.

B. Class III.

C. crossbite.

D. scissor bite.

E. deep bite.

Pytanie nr **147**

Schwarz provided data for the assessment of force values used in orthodontic treatment by introducing four stages of biological force application. The first degree of biological force application concerns forces:

- 1) that are sub-threshold;
- 2) of value up to 15 g/cm<sup>2</sup>;
- 3) exceeding the capillary blood pressure;
- 4) of value in the range of 20-50 g/cm<sup>2</sup>;
- 5) causing the destruction of periodontal tissues.

The correct answer is:

- A. 1,4.
- B. 1,2.
- C. only 3.
- D. 3,4.
- E. only 5.

Pytanie nr **148**

What kind of appliance is Schwartz plate, active labial arch and Adam's clasp on the first molars?

- A. functional.
- B. profilactic.
- C. retention.
- D. mechanical.
- E. mechanically-functional.

Pytanie nr **149**

Indicate the true statement concerning Tonn's Index:

- A. determines the correlation between the sum of upper permanent incisors' widths and the sum of lower molars' widths.
- B. determines the proper widths of dental arches in relation to four upper incisors' widths.
- C. determines the correlation between the sum of mesiodistal widths of mandibular and maxillary teeth.
- D. determines the correlation between the sum of upper permanent incisors' widths and the sum of lower permanent incisors' widths.
- E. determines the correlation between the width of the upper dental arch and the upper facial width.

Pytanie nr **150**

In the transversal symmetry analysis regarding the upper dental arch the palatal suture

line is used. This line is coincident with the sagittal midline line and is located by using:

- 1) anterior point situated between central incisors;
- 2) anterior point situated in the middle of the incisive papilla;
- 3) anterior point situated on the intersection of the second pair of palatal folds with the palatal suture;
- 4) posterior point situated on the border between the hard and soft palate between palatine foveae on the palatal suture;
- 5) posterior point defined by the tuberal line.

The correct answer is:

- A.** 1,4.
- B.** 2,4.
- C.** 2,5.
- D.** 3,4.
- E.** 1,5.

#### Pytanie nr 151

The space maintainer is:

- A.** active appliance, used for regaining space for unerupted premolar teeth.
- B.** passive appliance, used after premature extraction of a deciduous tooth.
- C.** functional appliance, which recreates the masticatory function after a loss of deciduous teeth.
- D.** active appliance, used after a loss of deciduous teeth.
- E.** true are A and D.

#### Pytanie nr 152

The standard polyamide Schönherr's vestibular plate (size three) is used in children of age:

- A.** 3 - 5 years.
- B.** 5 - 7 years.
- C.** 7 - 9 years.
- D.** 9 - 11 years.

E. 11-13 years.

Pytanie nr **153**

Which appliances are used to widen the palatal suture in the permanent dentition?

- A. Biedermann appliance, Haas appliance, Isaacson appliance, Derichsweiler appliance according to Karłowska.
- B. Haas appliance, Derichsweiler appliance, Nance appliance, Headgear.
- C. Haas appliance, Herbst appliance, Nance appliance, Delaire mask.
- D. Biedermann appliance, Herbst appliance, Jones-Jig, Delaire mask.
- E. Derichsweiler appliance according to Karłowska, Haas appliance, Herbst appliance, Lip-Bumper.

Pytanie nr **154**

Which malocclusion is treated with the simple inclined plane?

- A. total distocclusion.
- B. pseudodistocclusion.
- C. total open bite.
- D. partial anterior crossbite.
- E. malocclusion which is characterized by the negative functional test regarding the distal mandibular movement.

Pytanie nr **155**

An orthodontic mini implant inserted in an alveolar part of the mandible is an example of:

- A. intraoral, off the teeth, maximal anchorage.
- B. intraoral, tooth-type, reciprocal anchorage.
- C. intraoral, intermaxillary, maximal anchorage.
- D. extraoral, tooth-type, moderate anchorage.
- E. extraoral, off the teeth, minimal anchorage.

Pytanie nr 156

Which genetic syndrome is associated with mandibular hypoplasia?

- A. cleidocranial dysplasia.
- B. Treacher Collins syndrome.
- C. Crouzon syndrome.
- D. Apert syndrome.
- E. ectodermal dysplasia.

Pytanie nr 157

Which of the following arise from the lower part of the first pharyngeal arch?

- A. maxillary process.
- B. masseters.
- C. hyoid bone.
- D. facial muscles.
- E. styloid process.

Pytanie nr 158

Which of the following statements concerning Quad-Helix appliance is true?

- 1) the appliance is cemented on the upper first premolars and upper first permanent molars;
- 2) orthopedic and orthodontic effects are exerted in early mixed dentition;
- 3) the appliance consists of four helices;
- 4) the outer arms extend to the palatal surfaces of the upper incisors;
- 5) dental arch can be expanded asymmetrically.

The correct answer is:

- A. 1,2,3.
- B. 1,2,4.
- C. 1,2,5.
- D. 2,3,4.



E. 2,3,5.

Pytanie nr **159**

What types of pull are differentiated in an active, extraoral Headgear appliance?

- A. high pull (parieto-occipital); straight pull (combined); low pull (cervical).
- B. high pull (combined); straight pull (parieto-occipital); low pull (cervical).
- C. high pull (parieto-occipital); straight pull (cervical); low pull (combined).
- D. high pull (cervical); straight pull (combined); low pull (parieto-occipital).
- E. high pull (cervical); straight pull (parieto-occipital); low pull (combined).

Pytanie nr **160**

Indicate the true statement concerning reinclusion:

- A. it's a slow process during which the tooth moves away from the occlusal surface.
- B. the disturbance concerns primary molars or rarely first permanent molars.
- C. its aetiology is not fully explained.
- D. the differentiation between the tooth in retention and the submerged one is based on the fact that the latter is connected with the oral cavity by a canal covered with epithelium.
- E. all the above are true.

Pytanie nr **161**

Which of the following cephalometric measurements is used to assess the vertical face dimension?

- A. SNPg angle.
- B. ANB angle.
- C. interincisal angle.
- D. index.
- E. NSL line.

Pytanie nr **162**

The WITS appraisal according to Jacobson allows to determine:

- A. anterior facial height.
- B. posterior facial height.
- C. anteroposterior position of the maxilla in relation to the mandible.
- D. anteroposterior position of the maxilla in relation to the cranial base.
- E. direction of the mandibular rotation.

**Pytanie nr 163**

There are two methods of expanding the palate suture: RPE (rapid palatal expansion) and SPE (slow palatal expansion). Indicate the true statements about RPE:

- 1) allows you to activate the appliance 0.5-1 mm per day;
- 2) allows you to activate the appliance 1 mm per week;
- 3) active treatment lasts about 3 months;
- 4) active treatment lasts 2-3 weeks;
- 5) the suture opening rate is more physiological, similar to the rate at which a new bone forms.

The correct answer is:

- A. 1,4,5.
- B. 2,3,5.
- C. 2,4.
- D. 1,4.
- E. 1,3.

**Pytanie nr 164**

The springs, bended in the shape of a sinusoid, which connect the acrylic plates of an appliance are characteristic of:

- 1) Karłowska appliance type A, used for the treatment of distocclusions and a posterior functional position of the mandible, where sinusoid springs run from anterior lower part of the appliance in the canine region to posterior upper part of the appliance in the region of first permanent molars;
- 2) Karłowska appliance type B, used for the treatment of mesiocclusions and an anterior functional position of the mandible, where sinusoid springs run from anterior upper part of the appliance in the canine region to posterior lower part of the appliance in the region of first permanent molars;

3) Karłowska appliance type A, used for the treatment of mesiocclusions and an anterior functional position of the mandible, where sinusoid springs run from anterior lower part of the appliance in the canine region to posterior upper part of the appliance in the region of first permanent molars;

4) Karłowska appliance type B, used for the treatment of distocclusions and a posterior functional position of the mandible, where sinusoid springs run from anterior upper part of the appliance in the canine region to posterior lower part of the appliance in the region of first permanent molars;

5) Karłowska appliance type A, used for the treatment of distocclusions and a posterior functional position of the mandible, where sinusoid springs run from anterior upper part of the appliance in the canine region to posterior lower part of the appliance in the region of first permanent molars.

The correct answer is:

**A.** 1,2.

**B.** 1,4.

**C.** 2,3.

**D.** 3,4.

**E.** 2,5.

**Pytanie nr 165**

Secondary crowdings are the result of:

**A.** late growth of the mandible.

**B.** eruption of the third lower molars.

**C.** discrepancy between the amount of dental material and the size of the skeletal base.

**D.** premature loss of deciduous molars.

**E.** macrodontia in the upper dental arch.

**Pytanie nr 166**

Moyer's Index:

**A.** describes the correlation between the sum of permanent upper incisors widths SI and the sum of permanent lower incisors widths si.

**B.** defines the predictable space for premolars and canines (leeway space) based on the sum of permanent lower incisors widths.

**C.** defines the correlation between the sum of mesiodistal widths regarding maxillary and mandibular permanent teeth.

**D.** is used to define the arch length perimeter in relation to the sum of mesiodistal widths regarding 12 permanent teeth in the maxilla and mandible.

**E.** defines the correlation between the upper arch width and the upper facial width.

**Pytanie nr 167**

The hyrax screw enables to increase the maxillary expansion range of:

**A.** 15-20 mm.

**B.** 7-15 mm.

**C.** 1-7 mm.

**D.** 0.2 mm per month.

**E.** this screw is not used for this purpose.

**Pytanie nr 168**

Indicate the rules for the application of activators in distocclusions:

1) construction bite is taken;

2) upper labial bow is always active;

3) the guiding planes are created by removing acrylic from the anterior surface of lateral maxillary teeth and from the posterior side of mandibular teeth;

4) the guiding planes are created by removing acrylic from the posterior surface of maxillary teeth and in the mandible - from the anterior surface of lower lateral teeth;

5) labial bow is used only to remove tension created by the upper lip.

The correct answer is:

**A.** 1,2,3.

**B.** 1,3.

**C.** 1,4.

**D.** 1,4,5.

**E.** 1,2.

**Pytanie nr 169**

If the Bolton measurement (overall ratio) is 94.5% it suggests:

- A.** moderate crowding of the lower incisors.
- B.** increased height of the face.
- C.** reduced anterior width of the upper dental arch.
- D.** reduced posterior width of the upper dental arch.
- E.** enlarged width of the teeth in the lower dental arch.

**Pytanie nr 170**

Which of the following appliances is designed to expand the maxillary suture?

- A.** Haas appliance.
- B.** Karłowska appliance type A.
- C.** Karłowska appliance type B.
- D.** Herbst appliance.
- E.** Hawley appliance.

**Pytanie nr 171**

Second order bends:

- A.** correspond to buccolingual movements of particular teeth.
- B.** are briefly called in-set or off-set.
- C.** are bends in the vertical plane.
- D.** are bends enabling the control of the buccolingual tooth axis.
- E.** A and B are true.

**Pytanie nr 172**

Bolton's index evaluates:

- A.** predicted width of permanent canines and premolars based on the sum of the widths of permanent mandibular incisors.
- B.** predicted width of permanent canines and premolars based on the sum of the widths

of permanent maxillary incisors.

**C.** predicted width of permanent canines and premolars based on the sum of the widths of primary maxillary incisors.

**D.** relation between the sum of the widths of upper permanent incisors and the sum of the widths of lower permanent incisors.

**E.** relation between the sum of the widths of permanent maxillary teeth and the sum of the widths of permanent mandibular teeth.

### Pytanie nr 173

Indicate intraoral appliances which can be used in the treatment of mesiocclusions:

**A.** lower inclined plane, Frankel type IV appliance, Karłowska type B appliance, Stockfish kinetor, reverse Balters' bionator, open Klammt activator.

**B.** chin cup, Frankel type III appliance, palatal plate with oblique rim, Stockfish kinetor, open Klammt activator.

**C.** lower inclined plane, Frankel type III appliance, Karłowska type B appliance, open Klammt activator, reverse Balters' bionator.

**D.** Herbst appliance, headgear, vestibular shield, Frankel type I appliance, reverse Balters' bionator.

**E.** Headgear, Frankel type II appliance, Klammt activator, Metzelder activator, Twin-Block.

### Pytanie nr 174

Which of the following statements about the treatment with the face mask are **false**?

- 1) the face mask is an extraoral appliance used for maxillary protraction;
- 2) the best results are obtained when all permanent teeth are fully erupted;
- 3) maxillary deficiency is an indication for treatment;
- 4) the facemask is worn from 6 to 8 hours per day;
- 5) elastics can be attached to the fixed appliance.

The correct answer is:

**A.** 2,4.

**B.** 3,4.

**C.** 3,5.

**D.** 4,5.

**E. 1,5.**

**Pytanie nr 175**

Balters describes three types of his appliances. The second type of Balters appliance is used in treatment of:

- A.** distocclusions.
- B.** crossbites.
- C.** open bites.
- D.** mesiocclusions.
- E.** crowding.

**Pytanie nr 176**

In a 5-year-old child with lateral mandibular displacement the treatment of choice will be:

- 1) monobloc by Andresen;
- 2) vestibular plate;
- 3) exercises according to Skaloud;
- 4) inclined plane with 'wings';
- 5) selective grinding of primary molars.

The correct answer is:

- A.** 1,2.
- B.** 2,3.
- C.** 3,4.
- D.** 4,5.
- E.** only 5.

**Pytanie nr 177**

Which of the angles of Schwartz's analysis makes it possible to determine the position of the facial part of the skull relative to the brain part of the skull in the anteroposterior dimension?

- A.** angle F.

**B.** angle AB.

**C.** angle I.

**D.** angle H.

**E.** angle G.

**Pytanie nr 178**

Which of the following are parafunctions?

- 1) finger sucking;
- 2) pacifier sucking;
- 3) gnashing of teeth;
- 4) infantile type of swallowing;
- 5) constitutional breathing.

The correct answer is:

**A.** 1,2,3.

**B.** 1,2,4.

**C.** 1,4,5.

**D.** 2,4,5.

**E.** 3,4,5.

**Pytanie nr 179**

Physiological (physiognomical) face is divided into three segments: frontal, nasal and maxillary. The frontal segment is situated between:

**A.** Trichion and Ophryon points.

**B.** Ophryon and Subnasale points.

**C.** Subnasale and Gnathion points.

**D.** Trichion and Subnasale points.

**E.** Ophryon and Gnathion points.

**Pytanie nr 180**

Which of the following should be used in a 5-year-old child with anterior partial cross bite, with a positive functional test and existing spaces between the milk incisors?



- A. vestibular partial Kraus shield.
- B. vestibular plate by Hotz.
- C. palatal plate with an inclined oblique plane.
- D. Catlan's appliance.
- E. Karłowska appliance type A.

Pytanie nr **181**

Which of the following are characteristic of the dentition of a 3-year-old child?

- 1) dental arches are hemispheric;
- 2) line behind the second primary molars is inclined anteriorly (mesial step);
- 3) I Angle classes are present on molars;
- 4) 20 teeth are present;
- 5) occlusal plane is deepened.

The correct answer is:

- A. 1,2,3,4.
- B. 1,2,4.
- C. 1,3,4,5.
- D. 1,4.
- E. 1,4,5.

Pytanie nr **182**

Elastic (spring-loaded) appliances include:

- A. Bimler appliance, kinetor by Stockfisch, Karłowska appliance.
- B. Bimler appliance, Metzelder appliance, Karłowska appliance.
- C. kinetor by Stockfisch, Frankel appliance type I, Schwarz appliance.
- D. bionator by Balters, Frankel appliance type I, Bimler appliance.
- E. Wunderer appliance, bionator by Balters, Karłowska appliance.

Pytanie nr **183**

The asymmetric abnormal development of the first and second branchial arches is

associated with:

- 1) Goldenhar syndrome;
- 2) Crouzon syndrome;
- 3) Apert syndrome;
- 4) cleidocranial dysplasia;
- 5) hemifacial hypertrophy.

The correct answer is:

- A. only 1.
- B. 2,3.
- C. 4,5.
- D. 1,5.
- E. 1,4,5.

Pytanie nr **184**

Functional appliances **do not** include:

- A. Andresen activator.
- B. Klammt activator.
- C. Wunderer appliance.
- D. Lehman appliance.
- E. Schwarz appliance.

Pytanie nr **185**

The term 'translation' means:

- A. tooth displacement along its longitudinal axis towards the occlusal plane.
- B. parallel tooth displacement.
- C. tooth displacement along its long axis towards the skeletal base.
- D. movement in which the longitudinal axis of the tooth before and after the treatment forms a certain angle.
- E. root displacement in relation to the crown in the bucco-lingual direction.

Pytanie nr 186

In order to describe the morphology of maxillo-facial disorders maxillary orthopedists use many points, lines and planes known in anthropology. Even points include:

- A. ophryon.
- B. subspinale.
- C. prosthion.
- D. tragion.
- E. trichion.

Pytanie nr 187

Which of the following statements concerning extractions in orthodontics is true?

- 1) teeth with large restorations and teeth treated endodontically are preferred for extraction;
- 2) extractions in the upper arch are contraindicated in the maxillary buccal crossbite;
- 3) extractions are preferred when the nasolabial angle is decreased;
- 4) extractions are preferred when the interincisal angle is decreased;
- 5) premature loss of a primary canine on one side is an indication for the extraction of the primary canine on the same side of the other arch.

The correct answer is:

- A. only 1.
- B. 1,2.
- C. 1,2,3.
- D. 1,3,4.
- E. 1,4,5.

Pytanie nr 188

In Ricketts' profile analysis the esthetic line is determined by points:

- A. subnasale and pogonion.
- B. labrale superius and pogonion.
- C. columella and subnasale.

D. columella and pogonion.

E. pronasale and pogonion.

Pytanie nr 189

Which of the following are features of skeletal class III malocclusion?

- 1) class I molar relationships;
- 2) proclination of upper incisors;
- 3) retroclination of lower incisors;
- 4) increased overbite;
- 5) deep labiomental sulcus.

The correct answer is:

A. 1,2,3.

B. 2,3,4.

C. 2,3.

D. 1,5.

E. 3,5.

Pytanie nr 190

The malformation which occurs if in the 8th week of fetal life the embryo cephalic part does not move away from its caudal part is called:

A. mandibulo-facial dysostosis.

B. Cruzon syndrome.

C. Pierre Robin syndrome.

D. Ellis-van Creveld syndrome.

E. cranio-facial dysostosis.

Pytanie nr 191

Late incisor crowding is caused by:

A. premature loss of primary molars.

B. premature loss of primary canines.

- C. premature loss of primary incisors.
- D. late growth of the mandible.
- E. disproportionately large teeth in relation to the jaws.

Pytanie nr **192**

The asymmetrical genetically determined disorders include:

- A. Cruzon syndrome.
- B. Pierre Robin syndrome.
- C. Apert syndrome.
- D. Goldenhar syndrome.
- E. each of the above.

Pytanie nr **193**

Common features of cleidocranial dysplasia and mandibulofacial dysostosis are:

- 1) both syndromes are considered as symmetrical first and second branchial arch syndromes;
- 2) both syndromes are considered as asymmetrical first and second branchial arch syndromes;
- 3) occurrence of supernumerary teeth;
- 4) pseudo-prognathism;
- 5) discrepancies in development of maxilla and mandible.

The correct answer is:

- A. 1, 5.
- B. 2, 5.
- C. 1, 3.
- D. 1, 4.
- E. 2, 3.

Pytanie nr **194**

In treatment of a 4-year-old child with lip muscle hypotonia, distoclusion with incisor proclination and habitual mouth-breathing pattern, following method should be implemented:

- A. inclined plane.
- B. head cap with chin cap.
- C. Klammt appliance.
- D. Balters bionator.
- E. vestibular plate.

Pytanie nr **195**

Indicate correct sentences regarding the type 3 plaster:

- 1) also called model plaster, whose special variant is orthodontic plaster;
- 2) also called cast plaster, whose special variant is orthodontic plaster;
- 3) it is characterized by high porosity and low precision;
- 4) it is characterized by low porosity and high precision;
- 5) it is highly susceptible to abrasion and characterized by low stability of size.

The correct answer is:

- A. 1, 3, 5.
- B. 2, 3, 5.
- C. 2, 4, 5.
- D. 2, 4.
- E. 1, 4.

Pytanie nr **196**

Indicate features of titanium-molybdenum alloy:

- 1) it can be soldered and welded;
- 2) it cannot be soldered or welded;
- 3) it can be formed and bent, but can also fracture in case of sharp bends;
- 4) it demonstrates low friction;
- 5) it demonstrates high friction.

The correct answer is:

- A. 1, 3, 4.
- B. 2, 3, 4.
- C. 1, 3, 5.

D. 2, 3, 5.

E. 2, 5.

Pytanie nr **197**

“Appliance is intended for treatment of prognathism. The body of appliance is cut along the occlusal plane. (...) Construction bite is taken in maximum retractive position and substantial increase of vertical dimension of occlusion.” Above-mentioned description concerns:

A. Wunderer activator.

B. Metzelder appliance.

C. Ostrowski appliance.

D. Lehman appliance.

E. Balters bionator.

Pytanie nr **198**

“It happens when the point of force application lays apically towards the centre of tooth resistance, and centre of rotation is positioned coronally. In order to obtain only such movement, ratio of the torque to force acting on the tooth must be at least 12/1”. Above-mentioned description concerns:

A. uncontrolled tooth inclination.

B. controlled tooth inclination.

C. root movement or torque.

D. tooth translation.

E. none of the above mentioned.

Pytanie nr **199**

Choose **false** statements regarding the scissors bite:

A. broadening of the dental arch is observed.

B. narrowing of the dental arch might occur.

C. protrusion of the upper incisors or their retrusion.

**D.** facial features show disproportion in width of upper and lower face.

**E.** none of the above mentioned.

**Pytanie nr 200**

In relation to horizontal plane you can diagnose:

**A.** vertical maxillofacial disorders.

**B.** horizontal maxillofacial disorders.

**C.** dental arch asymmetries.

**D.** distocclusions.

**E.** none of the above mentioned.

**Pytanie nr 201**

Treatment of choice in case of an alleged diastema is:

**A.** frenuloplasty of the upper lip.

**B.** extraction of a supernumerary tooth.

**C.** observation.

**D.** waiting with an intervention until the upper canines erupt.

**E.** periodontic consultation.

**Pytanie nr 202**

Indicate features of orthodontic arch made of stainless steel:

1) ease of shaping, high plasticity;

2) high friction in relation arch-brackets;

3) it can be welded and soldered;

4) it can be used for correction of curve of Spee (by introducing sweep);

5) it can be a source of small, long active forces.

The correct answer is:

**A.** 1, 3, 5.

**B.** 2, 4.

**C.** 1, 3, 4.



**D.** 2, 3, 5.

**E.** only 3.

**Pytanie nr 203**

Theoretically “clean” distalization of maxillary molars with the use of Headgear can be achieved with the use of:

**A.** high pull headgear and short external arms parallel to the occlusal plane.

**B.** combined headgear with short external arms bent upwards.

**C.** low pull headgear with long external arms bent back.

**D.** low pull headgear with long external arms bent upwards.

**E.** high pull headgear with long external arms parallel to the occlusal plane.

**Pytanie nr 204**

Which of the below mentioned causes can lead to developing class II malocclusion?

1) finger-sucking;

2) persistent infantile type swallowing;

3) oral breathing pattern;

4) artificial feeding;

5) disfunction in lip seal, where the swallowing is performed with the tip of the tongue touching the upper lip;

6) disfunction in lip seal, where the swallowing is performed with the tip of the tongue touching the lower lip.

The correct answer is:

**A.** 1, 2, 3, 4, 6.

**B.** 1, 2, 3, 4, 5.

**C.** 1, 3, 5.

**D.** 1, 3, 4, 6.

**E.** 1, 2, 3, 4.

**Pytanie nr 205**

Choose correct features of arch wires made from nickel-titanium alloys:

1) shape memory;

2) high elasticity;

- 3) soldering ability;
- 4) source of low long-acting forces;
- 5) shaping ability.

Correct answer is:

**A.** 1, 2, 3.

**B.** 1, 2, 4.

**C.** 2, 3, 4.

**D.** 2, 4, 5.

**E.** 1, 3, 5.

#### Pytanie nr **206**

Which of the below mentioned craniometric points are odd?

- 1) Glabella;
- 2) Zygion;
- 3) Subspinale;
- 4) Prosthion;
- 5) Porion.

Correct answer is:

**A.** 1, 2, 3.

**B.** 2, 3, 4.

**C.** 1, 2, 4.

**D.** 2, 4, 5.

**E.** 1, 3, 4.

#### Pytanie nr **207**

Postural defect that exists for a long time can promote such occlusal defects as:

- A.** lateral mandibular displacement.
- B.** mesioclusion.
- C.** distoclusion.
- D.** both A and B are true.

E. both A and C are true.

### Pytanie nr 208

Choose **false** sentences regarding the friction force, which occurs during ortho treatment:

- A. it is determined by two factors: coefficient of friction and contact force.
- B. coefficient of friction is permanent for each material, and can be changed by the impact of the environment.
- C. contact force consists of the force of contact of both surfaces, plus ligating strength, stiffness of the wire and the size of the bracket's slot.
- D. for reduction of friction during ortho treatment, rigid arch wires with smooth surfaces and large diameter should be used.
- E. friction during ortho treatment can be reduced by using ligatures of low coefficient of friction and self-ligating brackets.

### Pytanie nr 209

Which of the below mentioned sentences describes torque?

- A. the centre of rotation lies in infinity, and the force acts through the centre of gravity. The M/F ratio is 10/1.
- B. the centre of rotation lies at the apex. In this case the torque to force ratio is between  $M/F=4/1$  to  $M/F=7/1$ .
- C. it occurs when the point of application lies apically to the centre of tooth resistance, and the centre of rotation is located coronally. In order to achieve only this movement, the torque to force ratio must be at least 12/1 of root movement or torque.
- D. the centre of rotation lies at the neck of the tooth. In such case the torque to force ratio is between  $M/F=10/1$  to  $M/F=12/1$ .
- E. it occurs when the point of application lies coronally to the centre of tooth resistance, and the centre of rotation is located apically. In order to achieve only this movement, the torque to force ratio must be at least 15/1.

### Pytanie nr 210

The use of pilot drill before placing the microimplant is recommended when the cortical layer is thicker than:

- A. 1 mm.
- B. 1.5 mm.
- C. 2 mm.
- D. 3 mm.
- E. using a pilot drill in placing microimplants is not recommended.

Pytanie nr **211**

Disorders in relation to 3 spatial planes include:

- 1) partial anterior open bite;
- 2) microgenia;
- 3) macrogenia;
- 4) complete deep bite;
- 5) micrognathia.

- A. 1,2.
- B. 2,3,5.
- C. 1,4.
- D. 2,3,4.
- E. all of the above.

Pytanie nr **212**

According to Jaruzelska, third increase in the vertical dimension is observed after reaching the occlusal plane by:

- A. medial primary incisors.
- B. first primary molars.
- C. second primary molars.
- D. first permanent molars.
- E. second permanent molars.

Pytanie nr **213**

Lateral margin for the upper and lower arch are:

- A. 2 mm in every direction in maxilla and 1.5 mm in every direction in mandible.
- B. 2.5 mm in every direction in maxilla and 1.5 mm in every direction in mandible.
- C. 2.5 mm in every direction in mandible and 1.5 mm in every direction in maxilla.
- D. 2 mm in every direction in mandible and 2.5 mm in every direction in maxilla.
- E. 2 mm in every direction in mandible and 1.5 mm in every direction in maxilla.

Pytanie nr **214**

Super-elastic NiTi arch wires **should not** be used:

- 1) during decreasing the horizontal overbite (overjet);
- 2) in order to finishing the process of levelling and control of vertical overbite;
- 3) as initial wires;
- 4) during closing the post-extraction spaces;
- 5) when using open springs for retrieving space.

- A. 1,2,3.
- B. 1,4.
- C. 2,3,4.
- D. 1,2,4,5.
- E. 3,4,5.

Pytanie nr **215**

There are two methods of palatal expansion: RPE (rapid palatal expansion) and SPE (slow palatal expansion). Select answers correct for SPE:

- 1) it allows for activating the device at the rate of 0.5-1 mm a day;
- 2) it allows for activating the device at the rate of 1 mm a week;
- 3) active treatment lasts for about 3 months;
- 4) active treatment lasts for 2-3 weeks;
- 5) suture opening rate is more physiological, similar to the rate at which new bone is forming.

- A. 1,4,5.
- B. 2,3,5.
- C. 2,4.
- D. 1,4.

E. 1,3.

Pytanie nr **216**

Indicate **false** statements regarding the bonding of orthodontic brackets:

- A.** in patients subjected to bleaching, lower bonding strength to the bleached enamel may occur.
- B.** chemical adhesion and coating the base of the bracket with silane agent is not recommended, as it increases the bonding force of the bracket to the tooth tissue.
- C.** the bonding strength of fixed appliance elements to the smooth surface of porcelain restoration is very small.
- D.** etching the porcelain surface with 37% phosphoric acid and silanization is recommended in order to increase the bonding strength.
- E.** newly made composite restorations do not require silanization in order to increase the bonding strength.

Pytanie nr **217**

In order for achieving orthopaedic expansion of the maxilla using RPE method, it is advisable to conduct treatment in:

- A.** adolescents during growth spurt.
- B.** children before growth spurt.
- C.** children before eruption of all primary teeth.
- D.** children after eruption of all permanent teeth.
- E.** adolescents before eruption of third molars.

Pytanie nr **218**

Using orthodontic mini-implants allows for:

- A.** obtaining permanent restoration of tooth loss.
- B.** introducing the intraoral anchorage.
- C.** obtaining significant shift of groups of teeth used as anchorage.
- D.** elimination of undesirable teeth shifts during orthodontic treatment.

**E.** elimination of skeletal anchorage treatment methods.

**Pytanie nr 219**

The minimal criteria for considering a functional test to be positive in case of functional prognathism, is the possibility of patient achieving following reaction during mandible revocation:

- A.** positive overjet.
- B.** positive overjet and overbite.
- C.** class I (Angle's classification).
- D.** class I (Angle's classification) and canine class I.
- E.** incisal edges contact - edge to edge.

**Pytanie nr 220**

The chances of assessing properly the developmental and dental age as percentage value basing on the calendar age amount to accordingly:

- A.** 40% for developmental age and 30% for dental age.
- B.** 65% for developmental age and 50% for dental age.
- C.** 80% for developmental age and 70% for dental age.
- D.** It is not possible to assess the developmental and dental age basing on the calendar age.
- E.** the developmental and dental age are similar to the calendar age.

**Pytanie nr 221**

The index which determines the estimated amount of space for premolars and canines basing on the sum of lower incisors' width, used in mixed and permanent dentition, is called:

- A.** Droschl's index.
- B.** Moyer's index.
- C.** Tonn's index.
- D.** Pont's index.

E. Bolton's index.

Pytanie nr **222**

Pseudo distocclusion is characterised by:

- 1) increase of SNA angle;
- 2) normal SNA angle and increased ANB angle;
- 3) decreased SNB angle;
- 4) I or II Angle's class;
- 5) I or II canine class;
- 6) hypotonic lower lip.

The correct answer is:

**A.** 2,3,6.

**B.** 1,4.

**C.** 3,4,5.

**D.** 1,4,6.

**E.** 2,3,4.