

Baza pytań do Lekarskiego Egzaminu Końcowego

General surgery

Pytanie nr 1

Which of the following operations can be performed in the case of adenocarcinoma localized in the sigmoid colon?

- A.** laparoscopic sigmoid resection.
- B.** Hartmann's procedure by means of laparotomy.
- C.** sigmoid resection by means of laparotomy.
- D.** laparoscopic Hartmann operation.
- E.** all the above.

Pytanie nr 2

The patient in poor general condition was transported to the hospital admission room. He reports a retrosternal pain and high fever. On the physical examination the crackling of the skin was palpable around the neck. The patient had been diagnosed with advanced oesophageal cancer. The chest CT showed the presence of air in the mediastinum, contrast leakage in the thoracic section of the esophagus and fluid effusion in the right pleural cavity. Indicate the optimal surgical procedures in this case:

- A.** a gastric probe, a ban on oral nutrition, antibiotic therapy.
- B.** stitching the oesophagus with an access via right-sided thoracotomy.
- C.** exclusion of the oesophagus through the emergence of oesophagostomy on the neck, mediastinal drainage, occlusion of the gastric gullet, further nutrition by nutritional gastrostomy.
- D.** oesophageal resection with gastroesophageal anastomosis in the cage chest.
- E.** implantation of a self-expanding stent with optional drainage of the right pleural cavity.

Pytanie nr 3

Which of the following can be classified as the grade II according to Hinchey classification of complications caused by diverticulitis?

- A. diverticulitis with para-colonic abscess.
- B. diverticulitis with pelvic abscess.
- C. diverticulitis with purulent peritonitis.
- D. diverticulitis with feculent peritonitis.
- E. Hinchey classification is not related to diverticulitis.

Pytanie nr 4

A 25-year-old woman found a lump of 2 cm x 1 cm in size in the upper lateral quadrant while self-examining her right breast. The biopsy result was ductal carcinoma. Considering the lymphatic drainage through the Roth path, the lymph node metastases may be expected in:

- A. first level of axillary lymph nodes.
- B. second level of axillary lymph nodes.
- C. third level of axillary lymph nodes.
- D. first and second level of axillary lymph nodes.
- E. second and third level of axillary lymph nodes.

Pytanie nr 5

Secondary peritonitis **does not** include:

- A. peritonitis related to chronic peritoneal dialysis.
- B. necrosis of the intestinal wall.
- C. peritonitis related to the leakage of an intestinal anastomosis.
- D. granulomatous peritonitis.
- E. fungal peritonitis.

Pytanie nr 6

Which of the following is an indication for the surgical treatment of the abdominal aortic aneurysm?

- A. diameter of the asymptomatic aneurysm exceeding 5.5 cm.
- B. diameter of the symptomatic aneurysm exceeding 2 cm.
- C. ruptured aneurysm.
- D. A,C are true.
- E. A,B,C are true.

Pytanie nr 7

The absolute indications for the surgical treatment of acute pancreatitis **do not** include:

- A. lack of improvement after conservative treatment.
- B. infected pancreatic necrosis.
- C. bleeding to the abdominal cavity.
- D. gastrointestinal perforation.
- E. abdominal compartment syndrome.

Pytanie nr 8

The treatment of tracheo-esophageal fistulas, which are a pathological connection between tracheal and esophageal lumina through an epithelium-covered canal, is very difficult and marked by numerous failures. Indicate the methods used for the treatment of tracheo-esophageal fistulas:

- 1) placing a tube into the stomach or intestine and conducting enteral nutrition;
- 2) placing a permanent self-expanding esophageal stent;
- 3) placing a temporary self-expanding stent in the trachea and esophagus;
- 4) attempts to close the fistula canal by means of repetitive ablation, biological glues and obliteration;
- 5) excision of the fistula with a segmental resection of the trachea and a primary esophageal sewage strengthened with a pedunculated tissue flap taken from the neighbourhood.

The correct answer is:

A. 1,3,5.

B. 1,4,5.

C. 2,3,4.

D. 2,4,5.

E. 3,4,5.

Pytanie nr 9

Which of the following is the most common cause of the mechanical ileus in the lower gastrointestinal tract?

A. diverticulosis of the colon.

B. peritoneal adhesions.

C. Meckel's diverticulum.

D. neoplastic tumors.

E. bezoars.

Pytanie nr 10

Abdominal compartment syndrome **does not** arise as a result of:

A. growing ascites.

B. excessive swelling of the intestine wall.

C. bleeding into the peritoneal cavity.

D. intestine distention due to gas accumulation.

E. lack of urine outflow.

Pytanie nr 11

Super obesity is an important risk factor for the cancer of:

A. pancreas.

B. gallbladder.

C. stomach.

D. colon.

E. thyroid.

Pytanie nr 12

A 27-year-old woman, with no chronic diseases was admitted to the Emergency Department due to fainting and severe abdominal pain lasting for 30 minutes. Blood pressure 80/60 mmHg, HR: 105 beats/min. Blood test: Hb: 12.5 g/dL, Hct: 41.5%, PLT: 251 000/mm³, Na: 135 mmol/L, K: 4.5 mmol/L, amylase: 463 U/L, total bilirubin: 0.7 mg/dL, β -hCG: 1.15 mIU/mL. The ultrasound examination in FAST algorithm showed trace of fluid around the spleen and in the pouch of Douglas. Indicate the most likely cause of the patient's abdominal pain:

A. ectopic pregnancy miscarriage.

B. acute pancreatitis.

C. ureteric colic.

D. mesenteric artery ischemia.

E. both A and B are correct.

Pytanie nr 13

Indicate **the false** statement concerning familial adenomatous polyposis (FAP):

A. it is autosomal dominantly inherited condition, the mutation concerns the *APC* gene.

B. the only surgery is proctocolectomy with end ileostomy.

C. colectomy with ileorectal anastomosis is performed in some patients.

D. there is an increased incidence of papillary thyroid cancer.

E. desmoid tumors form in the abdominal cavity.

Pytanie nr 14

Which of the following is the early complication after vascular surgery which can be diagnosed with ultrasound imaging?

- A.** true aneurysm.
- B.** false aneurysm.
- C.** perigraft abscess.
- D.** retroperitoneal hematoma.
- E.** seroma.

Pytanie nr 15

A 57-year-old man was admitted to the hospital with symptoms of acute pancreatitis. He has never been diagnosed with cholecystolithiasis, but he did abuse alcohol the night before. On admission Hct 46%, WBC 16,300/mm³, glucose 189 mg/dL, LDH 279 U/L, AST 193 U/L, serum Ca²⁺ 1.95 mmol/L, urea 1.50 mmol/L, PaO₂ 67 mmHg. On the third day at the hospital: Hct 40%, WBC 13,500/mm³, glucose 163 mg/dL, LDH 183 U/L, AST 170 U/L, serum Ca²⁺ 1.85 mmol/L, urea 1.73 mmol/L, PaO₂ 57 mmHg. According to the Ranson criteria in this patient:

- A.** severe pancreatitis is unlikely on admission and on the third day of hospitalization.
- B.** severe pancreatitis is unlikely on admission but it is probable on the third day of hospitalization.
- C.** severe pancreatitis is probable on admission and on the third day of hospitalization.
- D.** severe pancreatitis is probable on admission but it is unlikely on the third day of hospitalization.
- E.** provided data are not sufficient to assess the risk of severe pancreatitis.

Pytanie nr 16

Type I in the Bismuth classification of the bile duct injury denotes an injury of:

- A.** common hepatic duct < 2 cm from the hepatic duct confluence.
- B.** common hepatic duct > 2 cm from the hepatic duct confluence.
- C.** common bile duct only.

D. right or left hepatic duct.

E. at the level of the hepatic duct confluence.

Pytanie nr 17

The most common cause of intestinal fistulas is:

A. radiation-induced damage.

B. peritoneal adhesions.

C. Crohn's disease.

D. malignant neoplasm.

E. surgical complication.

Pytanie nr 18

Which of the following **are not** classified as internal abdominal hernias:

A. diaphragmatic hernias.

B. hernias of the paraduodenal recess.

C. pericaecal hernias.

D. hernias of the omental bursa.

E. lumbar hernias.

Pytanie nr 19

Which of the following is the urgent indication for the surgical operation in Crohn disease?

A. enterocutaneous fistula.

B. appearance of neoplasms (colon adenocarcinoma, intestinal lymphoma).

C. chronic subileus.

D. perianal fistula.

E. anorectal abscess.

Pytanie nr **20**

Indicate the most common direct cause of acute peritonitis:

A. strangulation of the small intestine.

B. intussusception of the small intestine into the large intestine.

C. perforation of the gastrointestinal tract.

D. sepsis.

E. large intestine obstruction.

Pytanie nr **21**

Which of the following is relative **contraindication** to conservative surgery in breast cancer?

A. tumour diameter exceeding 3 cm.

B. lack of patient's consent to conservative surgery.

C. synchronous bilateral breast cancer.

D. contraindications to radiotherapy.

E. breast cancer in males.

Pytanie nr **22**

Which of the following is the most common cause of the obstruction of the lower gastrointestinal tract?

A. colon cancer.

B. Crohn's disease.

C. intraperitoneal adhesions.

D. diverticulosis.

E. ulcerative colitis.

Pytanie nr 23

Indicate the **false** statement concerning diverticulosis of the gastrointestinal tract:

- A.** Meckel's diverticulum is the remnant of the fetal umbilical gastrointestinal duct and may contain ectopic foci of gastric or pancreatic tissue.
- B.** acquired diverticula are created by bulging the mucus membrane through the muscular layer of the intestine.
- C.** Meckel's diverticulum is a congenital and true diverticulum of the ileum located on the mesenteric edge of the intestine and its length can measure up to 15 cm.
- D.** colon diverticula appear usually in the 4th decade of life, they are often localized in the sigmoid colon and do not occur in the rectum.
- E.** complications of diverticular disease include inflammation, abscess, perforation, bleeding and mechanical obstruction.

Pytanie nr 24

Clinical manifestations related to Zenker's diverticulum include:

- A.** regurgitation, chest pain, functional obstruction.
- B.** regurgitation, aspiration, functional obstruction.
- C.** dysphagia, aspiration, functional obstruction.
- D.** dysphagia, aspiration, chest pain.
- E.** dysphagia, chest pain, functional obstruction.

Pytanie nr 25

The most common hypothesis on the development of varices refers their pathogenesis to:

- A.** weakened vein walls.
- B.** venous valves dysfunction.
- C.** increased hydrostatic pressure in the venous system.
- D.** use of anti-clotting agents.

E. A,B,C are true.

Pytanie nr 26

The indications for total parenteral nutrition include:

- 1) prolonged intestinal obstruction;
- 2) sepsis with the infection source in the abdomen;
- 3) fistula of the proximal small intestine with high secretion;
- 4) necessity to meet increased metabolic needs after severe trauma;
- 5) pseudobulbar palsy;
- 6) coma due to subarachnoid hemorrhage;
- 7) isolated frostbite of toes.

The correct answer is:

A. 1,2,3,4.

B. 1,2,5,6,7.

C. 1,3,4.

D. 1,2,5,7.

E. 1,3,4,5.

Pytanie nr 27

The antithrombotic prophylaxis **does not** involve:

A. use of low molecular weight heparin.

B. early mobilization of the patient.

C. use of compression stockings.

D. administration of acetylsalicylic acid.

E. limitation of fluid supply.

Pytanie nr 28

Which of the following should be performed in a patient who was referred to the surgical outpatient clinic because of yellowish skin?

- 1) laboratory exams: bilirubin, alkaline phosphatase, ALT, AST, GGT;

- 2) abdominal ultrasound;
- 3) hospitalization in order to perform endoscopic retrograde cholangiopancreatography;
- 4) magnetic resonance cholangiopancreatography (MRCP).

The correct answer is:

- A.** 1,2.
- B.** 1,3.
- C.** 1,4.
- D.** 2,3.
- E.** 1,2,3.

Pytanie nr 29

A 36-year-old woman was admitted to the Emergency Department (ED) after a car accident with symptoms of hemorrhagic shock. The ultrasound examination in FAST algorithm showed significant amount of free fluid in the peritoneal cavity. Blood pressure: undetectable, HR: 134 beats/min. At the ED four units of 0 Rh minus (-) red blood concentrate were transfused. Urgent laparotomy was performed. During the surgery another four units of red blood concentrate and four units of fresh frozen plasma were transfused. Which complications can occur as a result of these procedures?

- 1) thrombocytopenia;
- 2) coagulopathy;
- 3) hypocalcemia;
- 4) hypercalcemia;
- 5) hypokalemia;
- 6) hyperkalemia;
- 7) hypothermia.

The correct answer is:

- A.** 1,2,4,5,6,7.
- B.** 1,2,3,5,6,7.
- C.** 1,2,3,4,6,7.
- D.** 1,2,3,4,5,7.
- E.** 2,3,4,5,6,7.

Pytanie nr 30

The most common direct cause of peritonitis is:

- A. strangulation of the small intestine.
- B. intussusception of the small intestine into the large intestine.
- C. digestive tract perforation.
- D. sepsis.
- E. large bowel obstruction.

Pytanie nr **31**

The procedure consisting in cutting the esophageal muscles including the lower esophageal sphincter is performed in the patients with:

- A. Zenker's diverticulum.
- B. upper esophageal sphincter spasm.
- C. achalasia.
- D. diffuse spasm of the esophagus.
- E. C and D are correct.

Pytanie nr **32**

A 54-year-old woman came to the ER because of bloody stool. On physical examination: good verbal communication, apathy, tachycardia 120/min, blood pressure 90/60 mmHg, pale skin, abdominal walls at the level of costal margins, the abdomen soft on palpation with no peritoneal signs, hyperactive bowel sounds, fresh blood visible on *per rectum* examination. On lab tests: WBC 17 000/mm³, RBC 2.9x10⁶/mm³, HGB 8.7 g/dL, PLT 60x10³/mm³, APTT 40 s, INR 1.9. Additionally there is hepatitis B infection several years earlier in the medical history. Indicate the true statements:

- 1) the first step should be fluids infusion and blood transfusion in order to manage hypovolemic shock;
- 2) colonoscopy should be performed because the most probable place of the bleeding is located in the lower gastrointestinal tract;
- 3) blood tests should be repeated in short time to confirm active bleeding;
- 4) urgent gastroscopy is indicated;
- 5) gastric tube should be placed in the stomach to evaluate its contents which would allow

formulation of the correct diagnosis and proper treatment.

The correct answer is:

- A. 1,2,3.
- B. 2,3,5.
- C. 1,4.
- D. all the above.
- E. only 4.

Pytanie nr **33**

Ulcerative colitis is treated surgically. The gold standard in elective treatment is:

- A. Hartmann's colectomy.
- B. colectomy with ileorectal anastomosis.
- C. restorative proctocolectomy.
- D. restorative proctocolectomy with loop ileostomy.
- E. segmental colon resection.

Pytanie nr **34**

Extranodal lymphoma is most commonly localized in:

- A. stomach.
- B. duodenum.
- C. small intestine.
- D. colon.
- E. rectum.

Pytanie nr **35**

Indicate the **false** statement concerning spleen surgery:

- A.** the indication for splenectomy is: spleen trauma, hemolytic anemia, proliferative diseases, hypersplenism.
- B.** during radical gastrectomy or peripheral pancreatic resection, splenectomy is additionally performed.
- C.** splenectomy can be performed using both laparoscopy and classical technique.
- D.** after splenectomy vaccination against *Haemophilus influenzae* type B, meningococcal group C and seasonal influenza vaccinations are recommended.
- E.** the risk of fulminant sepsis after splenectomy is the greatest when the surgery is performed for hematological indications in the elderly.

Pytanie nr 36

A patient was admitted to the surgical ward with thermal burns of second degree covering the anterior surface of the chest and both upper limbs. Calculate the extent of the burns according to the rule of nines and the volume of fluids that should be given within 24 hours according to Parkland formula:

- A.** burn surface amounts to 27% of the total body surface, the volume can't be calculated because the body weight is not given.
- B.** burn surface amounts to 27% of the total body surface, the volume of fluids given within first 24 hours should be 2700 mL.
- C.** burn surface amounts to 36% of the total body surface, the volume can't be calculated because the body weight is not given.
- D.** burn surface amounts to 36% of the total body surface, the volume of fluids given within first 24 hours should be 3600 mL.
- E.** burn surface amounts to 40% of the total body surface, but the Parkland formula does not refer to the infused fluid volume.

Pytanie nr 37

A 35-year-old patient came to the ED complaining of a severe epigastric pain. The symptoms have lasted for over a dozen hours. Laboratory tests showed increased WBC, CRP and bilirubin concentration, decreased calcium ion concentration, increased activity of aminotransferases, amylase, lipase, LDH, GGTP and basic phosphatase. Abdominal ultrasound imaging showed a distension of intrahepatic bile ducts and blurred pancreatic outline. Indicate the correct management of this patient:

- A.** suspicion of acute hepatitis and diagnostics directed at a viral infection.
- B.** diagnosis of the perforation of a peptic ulcer and urgent laparotomy.
- C.** diagnosis of acute pancreatitis related to cholelithiasis and the preparation of the patient for ECPW.
- D.** suspicion of an aortic rupture based on the blurred outline of the pancreas.
- E.** presented data are too scarce to formulate the diagnosis.

Pytanie nr 38

Laparoscopic inguinal hernia repair with alloplastic material is classified as:

- A.** endoscopic operation - accompanied by tension.
- B.** endoscopic operation - tension-free.
- C.** open operation - tension-free.
- D.** open operation - accompanied by tension.
- E.** none of the above.

Pytanie nr 39

The most common direct cause of acute peritonitis is:

- A.** acute liver insufficiency.
- B.** intussusception of the small intestine into the large one.
- C.** perforation of the gastrointestinal tract.
- D.** large bowel obstruction.
- E.** acute pancreatitis.

Pytanie nr 40

Which of the following is the most common cause of upper gastrointestinal bleeding?

- A.** hemorrhagic gastritis.

- B.** esophagitis.
- C.** peptic ulcer.
- D.** gastric cancer.
- E.** Mallory-Weiss syndrome.

Pytanie nr **41**

The most frequent complication after thyroid surgery is:

- A.** bilateral recurrent laryngeal nerve paresis.
- B.** post-surgical hypocalcaemia.
- C.** bleeding into the post-surgical wound.
- D.** keloid.
- E.** thyroid storm.

Pytanie nr **42**

In the TNM classification of colon cancer T1 denotes infiltration of:

- A.** mucous membrane.
- B.** submucous membrane.
- C.** muscle membrane.
- D.** serous membrane.
- E.** neighboring organs.

Pytanie nr **43**

The type IV of Takayasu disease is characterized by inflammatory lesions located in:

- A.** arch of the aorta and its branches.
- B.** whole aorta and its branches.

C. descending aorta and its branches.

D. abdominal aorta and its branches.

E. pulmonary artery.

Pytanie nr 44

Which of the following concerning pancreatic cancer is true?

1) laparoscopy is contraindicated in surgical treatment;

2) jaundice may be one of the first symptoms and may indicate compression of the bile ducts;

3) head of the pancreas is the most common location;

4) curability is estimated at 50%;

5) women fall ill more often.

The correct answer is:

A. 1,3.

B. 2,3.

C. 2,4,5.

D. only 1.

E. only 3.

Pytanie nr 45

The arc of Riolan is an arterioarterial anastomosis between:

A. middle colic artery and the left colic artery.

B. superior mesenteric artery and internal iliac arteries.

C. left colic artery and the inferior mesenteric artery.

D. inferior mesenteric artery and iliac arteries.

E. iliac arteries and the right colic artery.

Pytanie nr 46

In Billroth I gastrectomy the reconstruction is completed with anastomosis between:

- A. esophagus and jejunum.
- B. esophagus and ileum.
- C. stomach and jejunum.
- D. stomach and duodenum.
- E. stomach and ileum.

Pytanie nr 47

The most common neuroendocrine pancreatic tumor is:

- A. *gastrinoma*.
- B. *somatostatinoma*.
- C. *VIPoma*.
- D. *glucagonoma*.
- E. *insulinoma*.

Pytanie nr 48

A 52-year-old obese woman went to see a gynecologist because of periodic bleeding from the reproductive tract. The abdominal ultrasound exam revealed incidentally a stone in the gallbladder of 2.5 cm in diameter. The patient was not aware of the cholelithiasis and she denies having any symptoms suggesting the disease. Which of the following is the optimal management?

- A. calming the patient and clinical follow-up.
- B. referral to the surgeon in order to perform elective cholecystectomy.
- C. urgent cholecystectomy.
- D. removal of the stone during endoscopic retrograde cholangiopancreatography (ERCP).
- E. referral for computed tomography in order to extend the diagnostics.

Pytanie nr 49

Which of the following concerning Meckel's diverticulum is **false**?

- A. it is present in about 2% of population.
- B. gastric mucosa or pancreatic tissue may be present in Meckel's diverticulum.
- C. most common complication of Meckel's diverticulum is mechanical obstruction (volvulus or intussusception).
- D. it is recommended to remove Meckel's diverticulum during the surgical treatment of diffuse peritonitis induced by other causes.
- E. second most common complication of Meckel's diverticulum is bleeding.

Pytanie nr **50**

Which of the following concerning intestinal obstruction is **false** ?

- A. classical symptoms of intestinal obstruction include: abdominal pain, nausea and vomiting, abdominal distension and constipation.
- B. in the case of mechanical obstruction of the small intestine, the pain is colic, intermittent, related to peristaltic waves.
- C. most common causes of mechanical obstruction of the small intestine are peritoneal adhesions resulting from previous surgery, hernias and neoplasms.
- D. most common causes of mechanical obstruction of the large intestine are colon cancer, diverticulitis and sigmoid volvulus.
- E. relatively weak pain occurring in waves, located mainly in the umbilical and lumbar regions is observed in obstruction caused by acute intestinal ischemia.

Pytanie nr **51**

The causes of hypertonic dehydration **do not** include:

- A. insufficient water supply.
- B. hyperventilation.
- C. hypoventilation.
- D. watery diarrhea.

E. sweating.

Pytanie nr **52**

Arterial embolism most commonly occurs:

- A. in the subclavian artery.
- B. in the brachial artery.
- C. in the splenic artery.
- D. at the point of origin of the internal carotid artery.
- E. at the point of origin of the deep femoral artery.

Pytanie nr **53**

The most frequent cause of chronic bleeding in the lower gastrointestinal tract is:

- A. colon polyps.
- B. ulcerous colitis.
- C. colon cancer.
- D. hemorrhoids.
- E. diverticulosis.

Pytanie nr **54**

Standard treatment for stomach ulcers is:

- A. total stomach resection.
- B. pharmacological treatment.
- C. subtotal stomach resection.
- D. highly selective vagotomy.
- E. light diet.

Pytanie nr **55**

The most common symptoms of so-called 'acute abdomen' **do not** include:

- A. positive Blumberg sign.
- B. increased peristaltic sounds, a so-called 'storm over the abdomen'.
- C. vomiting.
- D. abdominal guarding.
- E. abdominal distension.

Pytanie nr **56**

During the operation consisting in the resection of the right liver lobe, because of the wrong cut the hepatic flexure of the colon was injured which led to its perforation and the intestinal contents entered the peritoneal cavity. What is the correct classification of such a wound?

- A. clean-contaminated.
- B. dirty.
- C. contaminated.
- D. clean.
- E. secondary.

Pytanie nr **57**

Indicate the true statement concerning Charcot's triad:

- A. refers to cholecystitis.
- B. refers to colon diverticulitis.
- C. is characterized by epigastric pain, jaundice, recurrent fever and chills.
- D. is characterized by left side hypogastric pain, diarrhoea, recurrent fever and chills.
- E. is an indication for cholecystectomy.

Pytanie nr **58**

Which of the following concerning carcinoma of the ampulla of Vater is **false**?

- A.** predominant sign of carcinoma of the ampulla of Vater is painless mechanical jaundice.
- B.** carcinoma of the ampulla of Vater may lead to so called Courvoisier's sign.
- C.** percentage of resection operations in carcinoma of the ampulla of Vater is significantly lower than in pancreatic head cancer.
- D.** long term results of treatment are better in carcinoma of the ampulla of Vater than in pancreatic cancer.
- E.** its incidence in males and females is similar.

Pytanie nr **59**

In the case of a pancreatic cyst, the surgery should be considered:

- 1) if it is a pseudocyst;
- 2) when a cyst connection to the duct of Wirsung has been visualized in MRI (magnetic resonance imaging) and endoscopic retrograde cholangiopancreatography (ERCP);
- 3) if there are complications (infection, bleeding);
- 4) when the diameter of the cyst is greater than 6 cm.

The correct answer is:

- A.** only 1.
- B.** 1,3.
- C.** 3,4.
- D.** only 4.
- E.** 1,2,4.

Pytanie nr **60**

Which of the following clinical symptoms is an indication for urgent surgery in Crohn's disease?

- A.** recurrent diarrhea.
- B.** impermeable intestinal obstruction.

C. massive bleeding.

D. B and C are true.

E. A, B, C are true.

Pytanie nr 61

Which of the following primarily affects the incidence of postoperative complications after surgical treatment of a peptic ulcer?

A. ulcer ethiology.

B. previous therapy with proton pump inhibitors.

C. previous therapy with H₂-blockers.

D. time from the first perforation symptoms to the surgery.

E. patient sex.

Pytanie nr 62

Endemically iodine deficient areas are characterized by an increased incidence of the following cancer:

A. papillary carcinoma.

B. anaplastic carcinoma.

C. follicular carcinoma.

D. medullary carcinoma.

E. papillary and follicular carcinoma.

Pytanie nr 63

Which of the following is a late symptom of acute limb ischemia?

A. paresthesias.

B. muscle weakness.

- C.** flattened superficial veins.
- D.** oedemas.
- E.** coldness of ischemic parts of the limb.

Pytanie nr **64**

Short bowel syndrome may be caused by:

- A.** extensive resection of the small intestine.
- B.** fistula between the stomach and the transverse colon.
- C.** cecum-skin fistula.
- D.** A, B, C are true.
- E.** A and B are true.

Pytanie nr **65**

The 3rd class in ASA (American Society of Anesthesiologists) physical status classification system denotes:

- A.** healthy patient, without any comorbidities.
- B.** patient with a mild systemic disease.
- C.** patient with a severe but controlled systemic disease.
- D.** patient with a severe systemic disease posing a threat to their life.
- E.** patient who will probably not survive next 24 hours regardless the surgery.

Pytanie nr **66**

Which of the following is necessary in uncomplicated diverticulosis?

- A.** outpatient treatment with the use of a diet rich in fiber, rifaximin and antispasmodic drugs.
- B.** hospitalization which is absolutely necessary but it can go on in the internal medicine ward, intravenous antibiotic therapy.

C. urgent colonoscopy and making decision on the necessity and the type of treatment on the basis of endoscopic examination results.

D. outpatient treatment with the use of amoxicillin and metronidazol given orally.

E. indispensable hospitalization in the surgical ward, intravenous antibiotic therapy and observation because of the risk of diverticular perforation.

Pytanie nr 67

A patient with decompensated diabetes mellitus and severe ketoacidosis complains of abdominal pain, nausea and vomiting. There are no obvious signs of peritonitis on physical examination. The first-line approach in this patient is:

A. laparotomy.

B. minimally invasive exploratory laparotomy.

C. detailed abdomen diagnostics (CT, MRI).

D. appropriate hydration and correction of metabolic disturbances.

E. none of the above.

Pytanie nr 68

Which of the following accesses to the digestive tract can be used in nutritional therapy?

A. naso-gastric tube, gastrostomy, jejunostomy.

B. naso-gastric tube, gastrostomy, ileostomy.

C. esophagostomy, gastrostomy, jejunostomy.

D. gastrostomy, jejunostomy, ileostomy.

E. jejunostomy, ileostomy, colostomy.

Pytanie nr 69

In which of the following patients is an increased risk of perioperative complications observed?

1) obese;

2) above 30;

- 3) with coronary artery disease;
- 4) with diabetes mellitus;
- 5) classified to a ASA PS category I according to the American Society of Anesthesiologists.

The correct answer is:

- A.** 1,2,3,4.
- B.** 3,4,5.
- C.** 1,3,5.
- D.** 1,3,4.
- E.** 2,3,4.

Pytanie nr 70

Indicate the true statement concerning the incidence of hernias:

- A.** the most common are indirect inguinal hernias; less common are direct inguinal hernias, and the least frequent are femoral hernias; inguinal hernias occur more frequently in females.
- B.** the most common are indirect inguinal hernias; less common are direct inguinal hernias, and the least frequent are femoral hernias; inguinal hernias occur more frequently in males.
- C.** the most common are indirect inguinal hernias; less common are direct inguinal hernias, and the least frequent are femoral hernias; inguinal hernias occur in females and males with similar frequencies.
- D.** the most common are direct inguinal hernias; less common are indirect inguinal hernias, and the least frequent are femoral hernias; inguinal hernias occur more frequently in males.
- E.** the most common are femoral hernias; less common are direct inguinal hernias, and the least frequent are indirect inguinal hernias; inguinal hernias occur more frequently in females.

Pytanie nr 71

Contraindications to laparoscopic surgery include:

- 1) surgery in anamnesis;

- 2) peptic ulcer of the stomach rupture;
- 3) cardio-respiratory failure;
- 4) surgery because of cancer disease;
- 5) clotting disorders;
- 6) lack of patient's consent to this surgery.

The correct answer is:

- A.** 1,3,6.
- B.** 2,4,6.
- C.** 3,5,6.
- D.** only 6.
- E.** 4,3,6.

Pytanie nr 72

Which of the following is the most common cause of short bowel syndrome?

- A.** necrosis of the incarcerated intestine.
- B.** volvulus.
- C.** radiation exposure.
- D.** intestinal atresia.
- E.** mesenteric artery embolism.

Pytanie nr 73

Indicate the **false** statement concerning the epidemiology of pancreatic cancer:

- A.** etiological factors include high-lipid, high-protein diet and smoking.
- B.** tumour most commonly develops in the pancreatic body.
- C.** about 10-30% of the patients can be treated with the resection (pancreaticoduodenectomy).
- D.** 5-year survival rate is low (<10%).

E. duodenal ileus caused by the tumor is observed in about 10% of the patients.

Pytanie nr 74

The abdominal compartment syndrome **does not** lead to the decrease in:

- A. intracranial pressure.
- B. blood flow into the liver and its ischemia.
- C. venous return to the heart.
- D. blood flow through the intestinal wall.
- E. tidal volume.

Pytanie nr 75

What is the most common parenteral cause of mechanical obstruction of the small intestine in adults in developed countries?

- A. adhesions.
- B. cancer of the small intestine.
- C. trichobezoar.
- D. intussusception.
- E. parasitic infestation.

Pytanie nr 76

Which of the following may be a cause of ileus?

- A. diabetes.
- B. porphyria.
- C. biliary colic.
- D. renal colic.
- E. each of the above.

Pytanie nr 77

Paralytic ileus can be caused by:

- A. hypokaliemia.
- B. uremia.
- C. acute porphyria.
- D. uncontrolled diabetes.
- E. all the above.

Pytanie nr 78

Which of the following **does not** suggest the development of malignant melanoma from a nevus?

- A. enlargement of the nevus.
- B. bleeding nevus.
- C. equal distribution of pigment in the nevus.
- D. inflammation in the nevus.
- E. ulceration within the nevus.

Pytanie nr 79

A 42-year-old man is suffering from weight loss - 15 kg in 3 months, diarrhea, increased amount of urine, recurrent urinary tract infections and recurrent oral mucositis - was admitted to the hospital. The abdomen ultrasound examination visualized pancreatic head tumor. The tumor biopsy was performed during endoscopic ultrasonography. The most probable biopsy result is:

- A. pancreatic neuroendocrine tumor - VIP-oma.
- B. pancreatic neuroendocrine tumor - glucagonoma.
- C. metastasis of colorectal adenocarcinoma.
- D. pancreatic neuroendocrine tumor - insulinoma.

E. pancreatic neuroendocrine tumor - gastrinoma.

Pytanie nr 80

The following symptoms, such as rapid and irregular breathing, extension of the limbs in reaction to external stimuli, bilateral Babinski sign, impaired pupil reaction to light, increased blood pressure, pulse acceleration and increased sweating indicate the contusion of:

A. brain stem.

B. cerebellar hemisphere.

C. frontal lobes.

D. occipital lobe.

E. temporal lobe.

Pytanie nr 81

Ointments containing nitroglycerine are used in proctology. In which of the following diseases?

A. anal fistula.

B. perianal abscess.

C. haemorrhoidal disease.

D. pilonidal disease.

E. anal fissure.

Pytanie nr 82

A patient weighing 100 kg was admitted to the surgical ward because of the 3rd degree thermal burns of the anterior chest wall, abdomen and scrotum. Calculate the percentage of the burned body surface according to the rule of nines and the volume of fluids that should be transfused in the first 24h according to the Parkland formula:

A. burned body surface is 19% and the volume of fluids to be transfused within the first 24h is 7600 mL.

- B.** burned body surface is 19% and the volume of fluids to be transfused within the first 24h is 760 mL.
- C.** burned body surface is 10% and the volume of fluids to be transfused within the first 24h is 4000 mL.
- D.** burned body surface is 10% and the volume of fluids to be transfused within the first 24h is 400 mL.
- E.** burned body surface is 10% and the Parkland formula should not be used in patients with burns of the 3rd degree.

Pytanie nr **83**

Which of the following concerning pancreatic cancer is **false**?

- A.** more than 95% of cases of pancreatic cancer is ductal cancer, usually located in the body of pancreas.
- B.** mechanical jaundice may be the first sign of pancreatic cancer.
- C.** about 15-30% of pancreatic cancers are resectable at diagnosis.
- D.** primary surgical technique used in the treatment of cancer of the body of the pancreas is partial pancreatic resection.
- E.** TNM classification is the most commonly used method for the evaluation of tumour staging.

Pytanie nr **84**

Indicate the true statement concerning gastric cancer:

- A.** females are affected twice as often as males.
- B.** intestinal metaplasia does not increase the risk of the disease.
- C.** early gastric cancer does not spread to lymph nodes according to its definition.
- D.** treatment is mostly confined to chemo- and radiotherapy.
- E.** *Helicobacter pylori* infection 5-fold increases the risk of the disease.

Pytanie nr **85**

A patient is referred to the surgical outpatient clinic because of two tumours: one in the right adrenal gland with the diameter of 4.8 cm and the other in the left adrenal gland with the diameter of 2.1 cm (described as probable adenoma in CT). Laboratory tests excluded hormonal activity of the tumours. Which of the following is the management of choice in this patient?

- A. left adrenalectomy.
- B. right adrenalectomy.
- C. bilateral adrenalectomy.
- D. fine-needle aspiration biopsy of both tumours.
- E. observation and reevaluation after 12 months.

Pytanie nr **86**

The causes of hyperamylasemia include:

- 1) acute pancreatitis;
- 2) peptic ulcer perforation;
- 3) distal radius fracture;
- 4) ectopic pregnancy miscarriage;
- 5) renal failure;
- 6) cystitis;
- 7) acute appendicitis;
- 8) right foot toe paronychia.

The correct answer is:

- A. 1,2,4,5,6.
- B. 2,4,5,6,7.
- C. 1,2,4,5,7.
- D. 1,3,4,7,8.
- E. 3,5,6,7,8.

Pytanie nr **87**

In the Forrest classification of hemorrhages the grade II denotes:

- A.** recent hemorrhage.
- B.** active hemorrhage.
- C.** hemorrhage in the past.
- D.** no hemorrhage.
- E.** recurrent hemorrhage from non-healing wounds.

Pytanie nr **88**

In TNM classification of colon cancer the T4 denotes the infiltration of:

- A.** mucous membrane.
- B.** submucous membrane.
- C.** muscle membrane.
- D.** serous membrane.
- E.** surrounding organs.

Pytanie nr **89**

A 70-year-old patient comes to his family doctor complaining of the recurrent bleeding from the lower gastrointestinal tract. He usually has normal stools but occasionally mucous diarrhea occurs. The patient suspects bleeding from the hemorrhoids. Indicate the optimal diagnostics and treatment:

- A.** rectal examination and then referring the patient to colonoscopy in order to exclude pathological lesions in the upper segments of the colon.
- B.** rectal examination, calming the patient down because the symptoms are typical of bleeding hemorrhoids, referral to a surgeon.
- C.** referral to CT imaging, because it is the most precise examination to assess the colon.
- D.** rectal swab for parasite examination, because the symptoms may suggest enterobiasis.
- E.** referral to colonoscopy, as rectal examination may be omitted if the patient is to undergo endoscopic examination.

Pytanie nr 90

The surgical treatment of inguinal hernias with the Lichtenstein technique:

- A. consists in laparoscopic inguinal canal plasty.
- B. consists in inguinal canal plasty by placing sutures on the deep inguinal ring.
- C. consists in open inguinal canal plasty with the use of synthetic mesh.
- D. has been forbidden for many years.
- E. is not an existing method of surgical treatment.

Pytanie nr 91

A 35-year-old patient was admitted to the surgical ward with the diagnosis of acute pancreatitis in the course of alcohol use disorder. The patient complains of epigastric pain and vomiting. In the imaging studies cholelithiasis has been excluded, and acute edematous pancreatitis has been confirmed without any pathological cysts in the pancreatic area. There are no signs of cholangitis and inflammatory markers are low.

Indicate the correct management:

- A. urgent laparotomy and a drainage of the peritoneal cavity.
- B. discharge after 24 hour observation.
- C. conservative treatment until the normalization of laboratory test results and the relief of symptoms.
- D. laparoscopic cholecystectomy.
- E. ERCP or MRCP.

Pytanie nr 92

The commonest complication after thyroidectomy is:

- A. postoperative bleeding.
- B. hypoparathyroidism.
- C. damage to the recurrent laryngeal nerve.

D. surgical site infection.

E. recurrent goiter.

Pytanie nr **93**

The anterior wall of the inguinal canal is formed by:

A. aponeurosis of the abdominal external oblique muscle.

B. abdominal external oblique muscle.

C. transverse abdominal muscle.

D. abdominal external oblique muscle with the transverse abdominal muscle.

E. transverse fascia.

Pytanie nr **94**

Regional anaesthesia **does not** include:

A. epidural anaesthesia.

B. analgosedation.

C. plexus anaesthesia.

D. spinal anaesthesia.

E. infiltrative anaesthesia.

Pytanie nr **95**

A patient hospitalized due to acute pancreatitis for two weeks, felt epigastric pain accompanied by increasing fever about three weeks after the discharge from the ward. There is a tumour palpable in the epigastrium. Which of the following is the most probable diagnosis?

A. pseudocyst.

B. abscess.

C. true cyst.

D. pancreatic cancer.

E. recurrence of pancreatitis.

Pytanie nr 96

The most frequent origin of metastasis in the liver is:

A. prostate cancer.

B. colon cancer.

C. kidney cancer.

D. thyroid cancer.

E. parathyroid cancer.

Pytanie nr 97

Which of the following ranks among tension-free surgical techniques used in inguinal hernia:

A. Halstead procedure.

B. Lichtenstein procedure.

C. Shouldice procedure.

D. Bassini's procedure.

E. Girard procedure.

Pytanie nr 98

A young man came to the clinic. He noticed a periodic leaking of purulent content in the upper part of the gluteal cleft. There is a periodic pain in that area. The examination reveals several openings in the skin in the area, without any leakage. The most probably diagnosis is:

A. perianal fistula.

B. perianal abscess (in the phase without inflammation).

C. anal fissure.

D. cutaneous form of ulcerative colitis.

E. pilonidal cyst.

Pytanie nr 99

Indicate tests that should be ordered before the abdominal puncture in a patient with hepatic cirrhosis:

A. ultrasound imaging, whole blood count, PET, AIAT, AspAT, Na, K, Cl.

B. whole blood count, clotting tests, abdominal ultrasound imaging.

C. whole blood count, abdominal CT scan, ultrasound imaging, alkaline phosphatase, ammonia.

D. abdominal CT scan, glucose, urea, bilirubin, whole blood count.

E. clotting tests, AIAT, AspAT, bilirubin, albumin.

Pytanie nr 100

Indicate the minimal BMI value recommended for the qualification to surgical treatment of obesity in patients without comorbidities:

A. 50.

B. 45.

C. 40.

D. 35.

E. 30.

Pytanie nr 101

A female patient was urgently operated because of the bleeding from a liver rupture and during the surgery the Pringle maneuver was performed. This maneuver is associated with a compression of:

1) splenic artery;

2) proper hepatic artery;

3) right gastric artery;

- 4) splenic vein;
- 5) proper hepatic vein;
- 6) portal vein;
- 7) common bile duct.

The correct answer is:

- A.** 1,2,3.
- B.** 1,4.
- C.** 2,5,6,7.
- D.** 2,5,7.
- E.** 2,6,7.

Pytanie nr 102

Indicate the true statement concerning acute pancreatitis (AP):

- A.** main causes of AP are gallstones and drug abuse.
- B.** in 50% of patients the AP has the form of severe necrotic pancreatitis.
- C.** in the course of AP the increase in serum lipase activity lasts longer than the increase in amylase activity.
- D.** endoscopic retrograde cholangiopancreatography should be performed in all patients with the diagnosis of AP.
- E.** when severe necrotic pancreatitis is diagnosed, the treatment of choice is surgery.

Pytanie nr 103

Jaworski, Rovsing's and Blumberg signs are typical of:

- A.** cholecystitis.
- B.** renal colic.
- C.** cecum cancer.
- D.** appendicitis.

E. colon perforation.

Pytanie nr **104**

The type I according to Bormann's morphological classification of advanced gastric cancer denotes:

A. polypoid fungating tumor.

B. ulcerative tumor with elevated distinct borders.

C. ulcerative tumor with indistinct borders.

D. diffuse tumor (*linitis plastica*).

E. Bormann's classification concerns early gastric cancer only.

Pytanie nr **105**

The possible complications of anesthesia and surgery include:

1) nausea and vomiting;

2) hiccup;

3) pneumonia;

4) respiratory failure;

5) delirium;

6) urinary retention;

7) pulmonary embolism;

8) wound infection.

The correct answer is:

A. all the above.

B. 1,3,4,5,7,8.

C. 1,5,6,8.

D. 1,3,7,8.

E. 2,5,6,7.

Pytanie nr **106**

Tertiary hyperparathyroidism develops as a consequence of:

- A.** increased release of tropic hormone.
- B.** chronic kidney failure and dialysis therapy.
- C.** autonomic, increased PTH release occurring after kidney transplantation.
- D.** parathyroid carcinoma.
- E.** parathyroid adenoma.

Pytanie nr **107**

Indicate the true statement concerning Meckel's diverticulum:

- A.** it is a true diverticulum.
- B.** it is the most common congenital defect of the gastrointestinal system.
- C.** it consists of all the layers of the intestinal wall.
- D.** it may include elements of pancreatic tissue.
- E.** all the above.

Pytanie nr **108**

Indicate factors promoting thromboembolic complications:

- 1) age;
- 2) obesity;
- 3) long duration of surgery;
- 4) pelvic and hip surgery;
- 5) upper extremity surgery;
- 6) vitamin K deficiency;
- 7) pregnancy;
- 8) use of oral hormonal contraceptives;
- 9) varicose veins of the lower extremities;
- 10) neoplastic disease.

The correct answer is:

- A.** 2,3,4,5,7,8,9.
- B.** 1,2,4,6,7,8,9,10.
- C.** 1,2,3,4,7,8,9,10.

D. 1,2,6,7,8,9,10.

E. 2,3,4,5,8,9,10.

Pytanie nr **109**

Which of the following symptoms indicate the need for rectal cancer diagnosis?

- 1) tarry stools;
- 2) bleeding during defecation;
- 3) change of bowel habits;
- 4) anal itching;
- 5) elevated leukocytosis;
- 6) pencil-thin stools.

The correct answer is:

A. 1,5,6.

B. 2,3,4.

C. 1,2,6.

D. 2,3,6.

E. 1,3,4.

Pytanie nr **110**

Which of the following **is not** characteristic of deep vein thrombosis?

A. Moses' sign.

B. Ponten's sign .

C. Homans' sign.

D. increased tension of the tissues beneath the crural fascia.

E. pain deep in the calf and the popliteal fossa occurring after a passive flexion of the foot.

Pytanie nr **111**

Kwashiorkor is a form of malnutrition caused by a lack of:

- A. saturated fats.
- B. unsaturated fats.
- C. carbohydrates.
- D. proteins.
- E. water.

Pytanie nr **112**

A 68-year-old woman came in the evening to the ER because of colic abdominal pain, fecal vomiting, intermittent diarrhea and constipation for 7 days, and the presence of fresh blood in the stool. She reports she had lost 12 kg for the last 3 months without any specific diet. On physical examination the abdomen is distended, without muscle guarding, with audible resonant peristaltic sounds. On *per rectum* examination - the rectal ampulla is empty. Indicate the correct management:

- A. admission to the internal medicine ward for the hospital observation.
- B. abdominal ultrasound imaging and the observation in the out-patient settings.
- C. urgent out-patient colonoscopy.
- D. admission to the general surgery ward and qualification to the surgical treatment of the ileus.
- E. discharging the patient to home and referral for the control visit in the surgery out-patient clinic on the next day.

Pytanie nr **113**

Indicate the true statements concerning Lynch syndrome (hereditary nonpolyposis colorectal cancer):

- 1) it is an autosomal dominantly inherited disease;
- 2) one of its variants is Gardner's syndrome;
- 3) diagnosis is based on the Amsterdam criteria;
- 4) age of onset is usually between 20-30 years of life;
- 5) adrenal cancer is more common.

The correct answer is:

- A. 1,3.

B. 2,3.

C. 2,4,5.

D. only 1.

E. only 3.

Pytanie nr 114

A 40-year-old man, 80 kg of weight, was admitted to the ER with third-degree burns on the left upper limb, left lower limb and perineum. What amount of fluids should be administered during the 24 hours?

A. approx. 2 litres.

B. approx. 9 litres.

C. approx. 15 litres.

D. patient needs only oral rehydration.

E. described degree and extent of the burns do not require the use of intensive fluid therapy.

Pytanie nr 115

A 58-year-old, obese patient called at the family doctor because of abdominal pain, high fever with shivering and a yellowish shade of the eye whites which occurred several hours before her visit. After arriving at the emergency department CNS symptoms occurred in the form of conscious disturbances. The described signs and symptoms indicate:

A. viral meningitis.

B. abdominal abscess.

C. acute cholangitis.

D. aggravation of viral hepatitis.

E. acute coronary syndrome (the inferior wall).

Pytanie nr 116

McBurney's point is:

- A.** place that marks the attachment of inguinal ligament to the pubic bone - the orientation point important in hernia surgery.
- B.** place of the greatest pain occurring in acute cholecystitis.
- C.** place of the connection between the small and large intestines.
- D.** place at 1/3 of the distance between the anterior superior iliac spine and the umbilicus, that corresponds to the most common location of the base of the appendix.
- E.** place where the celiac trunk branches from the abdominal aorta.

Pytanie nr 117

Which of the following is the most successful method to obtain hemostasis in the case of the bleeding from esophageal varices which could not be stopped endoscopically or when urgent endoscopy is not available?

- A.** total gastric resection.
- B.** infusion of antihemorrhagic agents and proton pump inhibitor.
- C.** Sengstaken-Blakemore tube.
- D.** propranolol at a dose of 40 mg daily.
- E.** Foley catheter introduced to the esophagus.

Pytanie nr 118

The local complications of acute pancreatitis include:

- 1) portal vein thrombosis;
- 2) true pancreatic cyst;
- 3) pancreatic pseudocyst;
- 4) pancreatic fistula;
- 5) abscess.

The correct answer is:

- A.** 1,2,4,5.
- B.** 1,3,4,5.

C. 2,3,4,5.

D. 2,4,5.

E. 1,2,3.

Pytanie nr 119

Which of the following **is not** considered in the differentiation of acute appendicitis?

A. left-sided nephrolithiasis.

B. mesenteric lymphadenitis.

C. Meckel diverticulitis.

D. ruptured ectopic pregnancy.

E. Crohn's disease.

Pytanie nr 120

The Sengstaken-Blakemore tube is used in:

A. evaluation of gunshot wounds to the torso.

B. enteral nutrition after operative treatments.

C. rectal evaluation during endoscopic ultrasound.

D. temporary stoppage of hemorrhage from esophageal varices.

E. assessment of the biliary tract during endoscopic retrograde cholangiopancreatography.

Pytanie nr 121

Surgical complications from gastric and duodenal ulcers have become less common in the last decade. What is the main cause of this phenomenon?

A. use of truncal vagotomy.

B. use of truncal vagotomy together with antrectomy.

C. use of selective vagotomy.

D. use of highly selective vagotomy.

E. improved methods of conservative treatment.

Pytanie nr **122**

What is the most common location of arterial embolism?

A. division of the brachial artery into the radial and ulnar arteries.

B. division of the aorta into the common iliac arteries.

C. division of the common carotid artery.

D. division of the femoral artery into the deep artery of the thigh and the superficial femoral artery.

E. division of the popliteal artery into the arterial tibial artery and the tibial-fibular trunk.

Pytanie nr **123**

A 35-year-old motorcyclist was admitted to the ER after a traffic accident. He is unconscious. On physical examination: the abdomen is rigid, HR 140/min, BP 60/40 mmHg, GCS 3, on auscultation there is no respiratory sound over the left pleural cavity. On the FAST examination fluid is detected in the peritoneal cavity. Hb concentration is estimated at 6.5 g/dL on the arterial blood gas test. Indicate the correct sequence of necessary procedures:

A. full-body CT scan- laparotomy - drainage of the left pleural cavity.

B. chest X-ray - drainage of the left pleural cavity - laparotomy.

C. drainage of the left pleural cavity - laparotomy - full-body CT scan after stabilization of patient's general condition.

D. admission to ICU - massive blood transfusion - laparotomy after stabilization of patient's general condition.

E. laparotomy - drainage of the left pleural cavity - full-body CT scan after stabilization of patient's general condition.

Pytanie nr **124**

In which of the following breast areas breast cancer most frequently resides?

- A. retroareolar.
- B. upper inner quadrant.
- C. lower outer quadrant.
- D. lower inner quadrant.
- E. upper outer quadrant.

Pytanie nr **125**

Which of the following is recommended in the case of stage T3 cecum cancer?

- A. endoscopic mucosal resection.
- B. right hemicolectomy.
- C. resection of the cecum with appendectomy.
- D. ileo-transverso-anastomosis bypass.
- E. Hartmann procedure.

Pytanie nr **126**

Which hernia is Mayo technic used for?

- A. inguinal.
- B. hiatal.
- C. femoral.
- D. obturator.
- E. umbilical.

Pytanie nr **127**

Total gastrectomy is one of the surgical methods in the treatment of gastric cancer. Reconstruction of the digestive tract continuity is performed during this procedure. Which type of anastomosis is used in this technique?

- A. esophagoduodenal and entero-enteric.
- B. esophago-enteric and entero-enteric.
- C. gastroenteric and entero-enteric.
- D. entero-enteric only.
- E. esophago-transverse and entero-enteric.

Pytanie nr **128**

Which type of gastric resection is used in the surgical treatment of morbid obesity?

- A. subtotal gastrectomy.
- B. proximal gastrectomy.
- C. hemigastrectomy.
- D. gastric wedge resection.
- E. gastric sleeve resection.

Pytanie nr **129**

Which of the following is the best option of surgical palliative treatment in the case of a non-resectable tumor of the head of the pancreas that causes mechanical jaundice and duodenal obstruction?

- A. bypass anastomoses: gastric-intestinal, intestinal-intestinal and ductal- or bladder-intestinal.
- B. cholecystostomy.
- C. nutritional gastrostomy.
- D. attempt of non-radical tumor resection.
- E. diagnostic laparotomy only.

Pytanie nr **130**

Phlegmasia cerulea dolens (painful blue oedema) is caused by:

- A.** embolism.
- B.** thrombosis in one of the branches of the aortobifemoral bypass.
- C.** lymphoedema.
- D.** thrombosis in varices of the lower limbs.
- E.** generalized thrombosis of superficial and deep veins.

Pytanie nr **131**

Indicate the true statement concerning colon cancer:

- A.** its diagnosis is based on endoscopic biopsy followed by histopathological examination.
- B.** it rarely spreads to the liver and is the most common cause of a bowel obstruction.
- C.** it usually develops from polyp lesions.
- D.** A and C are true.
- E.** A,B,C are true.

Pytanie nr **132**

Early gastric cancer is defined as:

- A.** malignant neoplasm crossing the gastric wall, with metastases to the lymph nodes but with no metastases to the distant organs.
- B.** malignant neoplasm infiltrating the submucous membrane, but not crossing the gastric wall.
- C.** malignant neoplasm of the stomach categorized as T2 by the TNM classification.
- D.** malignant neoplasm in mucous and submucous membranes, but not infiltrating the muscle membrane of the stomach.
- E.** malignant neoplasm of the stomach diagnosed in a patient under 50 years of age.

Pytanie nr **133**

A 27-year-old woman with severe abdominal pain was admitted to the ER. She had fainted at home. She complains of the pain of the whole abdomen, lasting for 2 hours. The pain

had acute onset in the epigastric area. She can't remember the date of her last menstruation period, but she confirms no periods for more than a month. On palpation increase muscle tone and tenderness are observed. Other findings include pale skin, BP 80/60 mmHg, HR 120/min. Which condition should be excluded in the first place?

- A. rupture of an ectopic pregnancy.
- B. ovulation pain.
- C. appendicitis.
- D. irritable bowel syndrome.
- E. salpingitis.

Pytanie nr **134**

A Sengstaken-Blakemore tube is used in the management of:

- A. esophageal varices bleeding.
- B. duodenal ulcer bleeding.
- C. stomach erosion bleeding.
- D. Dieulafoy's lesion bleeding.
- E. hepatic cirrhosis.

Pytanie nr **135**

Indicate **the false** statement concerning acute cholecystitis:

- A. it's usually related to cholelithiasis.
- B. examination of choice is computed tomography.
- C. differential diagnostics should include right-side pneumonia and pleurisy among others.
- D. its complications include an empyema of the gallbladder and emphysematous cholecystitis.
- E. acute acalculous cholecystitis may be caused by several infectious agents including *Cytomegalovirus*, *Pneumocystis jiroveci* and *Isospora belli*.

Pytanie nr **136**

A 56-year-old patient was subjected to total thyroidectomy because of Grave's disease. Immediately after the removal of the tracheal tube the symptoms of acute respiratory failure occurred including stridor and dyspnea. The most probable reason for such symptoms is:

- A.** injury of the trachea during the intubation.
- B.** bilateral vocal fold paralysis with narrow glottis gap.
- C.** bilateral vocal fold paralysis with wide glottis gap.
- D.** postoperative bleeding at the site of the excised gland.
- E.** overdose of general anesthetics.

Pytanie nr **137**

The most common localization of colon cancer is:

- A.** cecum.
- B.** ascending colon.
- C.** transverse colon.
- D.** descending colon.
- E.** sigmoid colon and the rectum.

Pytanie nr **138**

Meckel's diverticulum consists of:

- A.** all layers of the intestinal wall.
- B.** mucous membrane only.
- C.** muscular layer only.
- D.** serous membrane only.
- E.** serous membrane and muscular layer.

Pytanie nr 139

Indicate the true statement concerning the keloid:

- A.** it occurs at the place of intense healing of the wound, and it is a hard, elevated reddish scar that develops at the place of the wound healing up to 6 months since the injury and then gradually disappears over the years.
- B.** it develops at the place of the wound and involves also the surrounding normal skin, it lasts longer than 6 months from the trauma; it most frequently affects the wounds of the upper chest and shoulders.
- C.** it is a kind of tissue that appears at the place of the healing epidermis.
- D.** it is a tissue occurring at the bottom of the wound healing by secondary intention.
- E.** it is a traditional name of the inflammatory infiltration that occurs in the area of an infected wound.

Pytanie nr 140

A patient complains of a dull, disturbing, diffuse, deep abdominal pain, which precise location he is unable to determine, but the pain is the strongest at the midline. The patient reports the pain resembles a pain that was accompanying the first symptoms of acute appendicitis 20 years ago. Such a pain is called:

- A.** phantom pain.
- B.** cluster pain.
- C.** somatic pain.
- D.** neuralgic pain.
- E.** visceral pain.

Pytanie nr 141

A 30-year-old woman, weighing 60 kg, was referred to the ER with III degree burnings of the left upper extremity, left lower extremity and of the groin. What volume of fluids should be administered within 24 hours?

- A.** approx. 7 litres.

- B.** approx. 2 litres.
- C.** approx. 15 litres.
- D.** she needs only oral fluids.
- E.** described degree and extent of burns do not need intensive fluid therapy.

Pytanie nr **142**

A 65-year-old patient 10 years after aorto-aortic prosthesis because of ruptured aortic aneurysm. For the last 3 months periodical fever. Today admitted to the ER with the symptoms of heavy upper gastrointestinal bleeding. On CT features of inflammatory infiltration around the prosthesis with gas vesicles. You should first suspect in this patient:

- A.** trapped gas syndrome after aortic aneurysm surgery.
- B.** necrotic haemorrhagic pancreatitis.
- C.** bleeding from an aorto-duodenal fistula.
- D.** forming of perianastomotic aneurysm.
- E.** oesophageal perforation.

Pytanie nr **143**

The Monteggia fracture is:

- A.** femoral intertrochanteric fracture.
- B.** facial fracture.
- C.** first metacarpal bone fracture with dislocation.
- D.** shaft of the ulna fracture with dislocation and luxation of the head of the radius.
- E.** fracture of the surgical neck of the humerus.

Pytanie nr **144**

The proper management in the case of rectal perforation accompanied by fecal peritonitis is:

- A.** partial resection of the rectum and making primary anastomosis.

- B.** to create a colostomy.
- C.** application of a prosthesis.
- D.** to create an anastomosis bypass.
- E.** peritoneal lavage and drainage.

Pytanie nr **145**

Which of the following **is not** an indication for the surgical treatment of chronic pancreatitis in every case?

- A.** severe pain that demands the use of opiates.
- B.** suspicion of a neoplastic tumor.
- C.** duodenal ileus.
- D.** pancreatic fistula.
- E.** any pseudocyst.

Pytanie nr **146**

The symptoms of the acute appendicitis with the appendix located behind the cecum include:

- A.** positive psoas sign.
- B.** Cullen's sign.
- C.** Charcot's triad.
- D.** Grey Turner's sign.
- E.** Halsted's sign.

Pytanie nr **147**

Which of the following **is not** an indication for the pleural drainage?

- A.** tension pneumothorax without dyspnea.

- B.** bilateral pneumothorax with an air rim of 2.5 cm.
- C.** pleural effusion in acute pancreatitis.
- D.** pleural empyema.
- E.** traumatic hemothorax.

Pytanie nr **148**

A Sengstaken-Blakemore tube is used to:

- A.** measure of pulmonary wedge pressure.
- B.** remove varices in the lower limbs.
- C.** perform colonoscopy.
- D.** temporarily stop the bleeding from esophageal varices.
- E.** remove gallstones during ERCP.

Pytanie nr **149**

Mitotane is used as an adjuvant therapy in the treatment of:

- A.** pancreatic cancer.
- B.** gastric cancer.
- C.** malignant melanoma.
- D.** adrenocortical carcinoma.
- E.** thyroid cancer.

Pytanie nr **150**

Which of the following hernias is accompanied by the loss of the angle of His?

- A.** sliding hiatal hernia.
- B.** Morgagni hernia.
- C.** Bochdalek hernia.

D. paraesophageal hernia.

E. B and D are correct.

Pytanie nr **151**

A woman comes to the ER and complains of left side hypogastric pain which started the previous evening, temperature 39°C. A hardly movable tumour is palpable in the left lower quadrant of the abdomen. You should suspect first:

A. irritable bowel syndrome.

B. acute diverticulitis.

C. Crohn's disease.

D. colon cancer.

E. acute pancreatitis.

Pytanie nr **152**

Indicate the true statements concerning esophageal cancer:

1) it has a good prognosis;

2) most common type of esophageal cancer is adenocarcinoma;

3) achalasia is one of its risk features;

4) it infiltrates surrounding tissues at early stages and metastases to the lymph nodes;

5) surgery is the primary mode of treatment.

The correct answer is:

A. 1,2,3,5.

B. 1,2,3.

C. 1,2,5.

D. 3,4.

E. 3,4,5.

Pytanie nr **153**

Internal hernias **do not** include:

- A. diaphragmatic hernia.
- B. parastomal hernia.
- C. pericecal hernia.
- D. paraduodenal hernia.
- E. foramen of Winslow hernia.

Pytanie nr **154**

Which of the following may be a complication of the thyroidectomy?

- A. hyperparathyroidism.
- B. hearing impairment.
- C. hypersalivation.
- D. facial nerve palsy.
- E. hypoparathyroidism.

Pytanie nr **155**

Which of the following organs is resected during Whipple's operation with Traverso modification?

- A. rectum.
- B. spleen.
- C. pancreas.
- D. thymus.
- E. liver.

Pytanie nr **156**

Kehr's drain is used in:

- A. thyroid surgery.

- B. bariatric surgery.
- C. thoracic surgery.
- D. biliary surgery.
- E. neurosurgery.

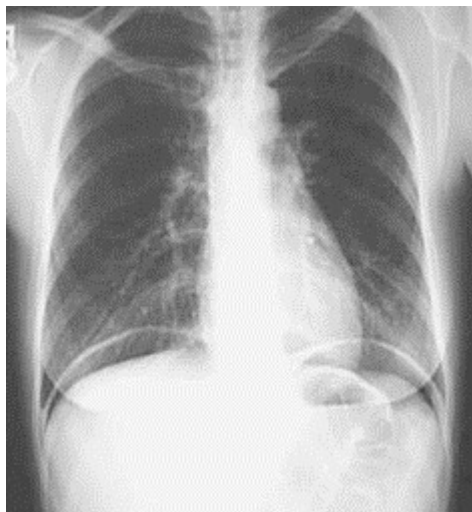
Pytanie nr **157**

Which of the following **is not** an indication for liver transplantation:

- A. post-inflammatory liver cirrhosis.
- B. Budd-Chiari syndrome.
- C. Wilson's disease.
- D. primary and secondary biliary liver cirrhosis.
- E. disseminated hepatocellular carcinoma.

Pytanie nr **158**

A 48-year-old gentleman with sudden severe epigastric pain was referred to the ER. Severe tenderness with a guarding and rebound sign over the upper, middle and lower abdominal regions was found on physical exam. Pulse rate was 120/min and blood pressure 100/60 mmHg. Blood testing revealed WBC 18.3 K/ μ L; serum amylase 85 U/L; serum lipase 42 U/L; CRP 183 mg/dL; total bilirubin 0.56 mg/dL. On abdominal imaging the empty gall bladder, CBD of 5mm in diameter and normal sized heterogenous pancreas with free fluid in the upper part of the peritoneal cavity. The results of the plain chest x-ray are shown in the picture. Which management would you recommend to this patient?



- A.** a discharge with prescribed pain killers, proton pump inhibitors and antibiotics and a follow-up visit the next day.
- B.** in-hospital intensive conservative treatment with pain killers, proton pump inhibitors and antibiotics.
- C.** in-hospital intensive conservative treatment with pain killers, proton pump inhibitors and antibiotics and performing upper endoscopy if clinical worsening occurs.
- D.** in-hospital intensive conservative treatment with pain killers, proton pump inhibitors and antibiotics and performing laparotomy if clinical worsening occurs.
- E.** in-hospital treatment with urgent surgery with concomitant pain killers, proton pump inhibitors and antibiotics.

Pytanie nr **159**

Which of the following should you suspect in a female patient complaining of cyclic regular hypogastric pain occurring for a longer time and rectal bleeding that accompanies menstruation?

- A.** Meckel's diverticulum.
- B.** hyperthyroidism.
- C.** intestinal tract endometriosis.
- D.** haemorrhagic diathesis.
- E.** none of the above.

Pytanie nr **160**

Which of the following **is not** observed in the course of pulmonary embolism?

- A.** marked increase in arterial pressure.
- B.** jugular vein distension.
- C.** tachypnea and tachycardia.
- D.** cold sweats.

E. agitation.

Pytanie nr 161

Which of the following must be performed first in the case of a patient with a liver tumor diagnosed incidentally on ultrasound and a suspicion of cancer metastasis?

- A.** accurate medical history, contrast enhanced CT of the abdomen, endoscopy of the upper and lower gastrointestinal tract.
- B.** accurate medical history and core needle biopsy of the tumor for histopathological examination.
- C.** accurate medical history and PET-CT as soon as possible.
- D.** accurate medical history, contrast enhanced CT of the abdomen and urgent decision on laparotomy and partial hepatectomy with tumor resection.
- E.** all the above statements are false.

Pytanie nr 162

A 45-year-old patient, a smoker abusing alcohol, has been admitted to the ED with severe abdominal pain. On admission the patient presents pale, wet skin, and complains of unbearable abdominal pain that intensifies while he moves. On examination the abdominal guarding and absent bowel sounds are noted. The patient reports that the pain started acutely in the epigastric region and then extended to the whole abdomen. Which of the following examinations should be performed in the first place?

- A.** abdominal ultrasound imaging.
- B.** chest X-ray and a plain frontal radiograph of the abdomen in erect posture.
- C.** abdominal CT.
- D.** gastroscopy.
- E.** none of the above.

Pytanie nr 163

During the surgery of the metastatic tumor of the liver, the surgeon performed, as he explained to the students, the Pringle maneuver. It consists in:

- A. temporal pressure of the inferior vena cava.
- B. introducing Kehr's drain into the right hepatic duct.
- C. breaking with the fingers the liver parenchyma to visualize the blood vessels and bile ducts, which facilitates their ligation.
- D. cutting off all the ligaments fixing the liver to ensure a free access to the rear hepatic segments.
- E. temporal clamping of the hepatic duodenal ligament to limit the inflow of blood to the liver.

Pytanie nr **164**

In the case of acute abdominal symptoms in a cachectic patient in a serious condition - large intestine perforation due to diverticulitis of the sigmoid colon - the operation of choice is:

- A. sigmoid resection with end-to-side anastomosis.
- B. Hartmann's procedure of the resection of the sigmoid colon.
- C. percutaneous drainage of the abdominal cavity.
- D. sigmoid resection with end-to-end anastomosis.
- E. abdominoperineal resection of the rectum.

Pytanie nr **165**

Indicate **the false** statement concerning erysipelas:

- A. is a superficial infection of the skin and connective tissue caused by streptococci.
- B. is characterized by a lack of a distinct skin injury - the infection may enter the skin even through a minor scratch.
- C. it may be complicated by the involvement of deeper tissues (a phlegmon, necrosis of the skin and subcutaneous tissue) and sepsis.
- D. recurrent erysipelas of lower limbs may lead to skin hardening and permanent edema of the limb.

E. there are no general symptoms of the infection.

Pytanie nr **166**

Indicate the **false** statement concerning hemorrhoids:

A. common causes of hemorrhoids are constipation as well as excessive pressure when passing stools.

B. very often hemorrhoids appear during pregnancy, probably due to hormones affecting the loosening of connecting tissue, constipation and baby head pressure on the pelvic soft tissues.

C. hemorrhoids may prolapse during defecation, but they spontaneously return to the anal canal - this is the example of the third stage of hemorrhoidal disease.

D. the main hemorrhoid symptoms are bleeding and prolapse, acute complications that require surgical treatment are thrombosis or hemorrhage.

E. all the statements are true.

Pytanie nr **167**

Which of the following is an extraintestinal symptom of Crohn disease?

A. optic neuritis.

B. lupus erythematosus.

C. pyoderma gangrenosum.

D. chronic venous insufficiency.

E. all the above.

Pytanie nr **168**

Pringle maneuver consists in the compression of:

A. hepatoduodenal ligament.

B. aorta.

C. inferior mesenteric artery.

D. superior mesenteric artery.

E. splenic artery.

Pytanie nr 169

A Richter's hernia is defined as:

A. every linea alba hernia.

B. every inguinal hernia in a woman.

C. a hernia that contains the Meckel's diverticulum.

D. a hernia that contains the antimesenteric wall of the intestine.

E. a hiatal hernia.

Pytanie nr 170

A 55-year-old patient came to the surgeon office with the following complaints: for several years fresh blood bleeding from the anus, which recently intensified, occasionally itching and burning sensation in this area; recently after defecation he repositions prolapsing nodules with his finger. This clinical picture allows of the diagnosis of hemorrhoids of:

A. I grade.

B. II grade.

C. III grade.

D. IV grade.

E. V grade.

Pytanie nr 171

The main symptoms of the large bowel obstruction are:

- 1) vomiting at the early stage of the disease;
- 2) alkalosis followed by metabolic acidosis;
- 3) immobilization of extracellular fluid in the so-called third space;
- 4) increased concentration of hemoglobin and hematocrit;
- 5) bowel distension with fluid accumulation.

The correct answer is:

A. 1,2,5.

B. 3,4,5.

C. 1,5.

D. 1,2.

E. 1,4,5.

Pytanie nr 172

Which of the following **is not** used in nutritional therapy?

A. PEG.

B. intravenous access.

C. sigmoidostomy.

D. gastric tube.

E. all of these accesses are used in nutritional therapy.

Pytanie nr 173

In the patient with head trauma caused by taking part in a traffic accident the following signs are observed:

- anisocoria L>R;

- opening eyes only in the response to strong pain;

- patient emits incomprehensible sounds;

- patient withdraws his hand when a venous catheter insertion is attempted.

What Glasgow Coma Score should be assigned to the patient and does the patient need intratracheal intubation?

A. GCS 9, the intubation is necessary.

B. GCS 9, the intubation is not necessary.

C. GCS 9, clinical data are not sufficient to determine indications for the intubation.

D. GCS 8, the intubation is not necessary.

E. GCS 8, the intubation is necessary.

Pytanie nr **174**

The surgical creation of the anastomosis between the stomach and the intestine modo Rydygier (Billroth's operation I) consists in:

- A. anastomosing the stomach to the small intestine.
- B. anastomosing the stomach to the ascending colon.
- C. anastomosing the stomach to the duodenum.
- D. anastomosing the stomach to the descending colon.
- E. B or D are true.

Pytanie nr **175**

An adult man who has fallen from the third floor is unconscious: he does not open eyes in response to pain, does not produce any sound, tenses up extensor muscles of the limbs, he extends and rotates internally his arms - he holds his limbs in an extended position.

What should his GCS score be?

- A. 1.
- B. 2.
- C. 3.
- D. 4.
- E. 5.

Pytanie nr **176**

Indicate the **false** statement concerning gastrointestinal stromal tumors (GIST):

- A. genetic disorders play an important role in their etiology.
- B. their most common localization in the gastrointestinal tract is the stomach.
- C. first-line treatment is their surgical removal.
- D. they are of epithelial origin.

E. adjuvant treatment is chemotherapy with imatinib.

Pytanie nr 177

According to the rule of nines, a burning of both lower limbs and the scrotum in adult patients affects:

- A. 19% of the body surface.
- B. 36% of the body surface.
- C. 37% of the body surface.
- D. 45% of the body surface.
- E. rule of nines is not related to burned body surfaces.

Pytanie nr 178

Which of the following **is not** an indication for urgent exploratory laparotomy after abdomen trauma?

- A. free gas in the peritoneal cavity.
- B. peritoneal signs on physical examination.
- C. totally absent peristalsis.
- D. shock of unknown origin.
- E. dissection of the ascending aorta.

Pytanie nr 179

Indicate the **false** statement concerning thyroid cancer:

- A. papillary cancers rarely occur in patients older than 40 and rarely give distant metastases.
- B. follicular cancer most frequently occur in patients aged 30-50 and spreads mainly through blood vessels.
- C. anaplastic cancer does not infiltrate surrounding tissues and rarely metastases to the lungs.

D. medullary cancer secretes calcitonin.

E. medullary cancer can occur as a part of MEN II syndrome.

Pytanie nr **180**

Lynch1 syndrome is characterized by occurrence of the following neoplasms:

A. colon cancer, endometrial cancer, ovarian cancer.

B. colon cancer, gastric cancer, small intestine cancer.

C. colon cancer, breast cancer, thyroid cancer.

D. thyroid cancer, parathyroid cancer, retinoblastoma.

E. colon cancer.

Pytanie nr **181**

Indicate the **false** statement concerning kwashiorkor malnutrition:

A. it is acute malnutrition presenting with hypoalbuminemia, oedemas, dyselectrolytemia, and consciousness impairment.

B. it usually occurs as a consequence of an acute disease, trauma or surgery in overweight or obese patients, who receive crystalloids only without protein supplementation.

C. weight loss is always observed in affected patients.

D. parenteral nutrition is recommended in this type of malnutrition.

E. fluid retention and oedemas occur.

Pytanie nr **182**

Which of the following is the most common source of metastases to the liver?

A. colon cancer.

B. pancreatic cancer.

C. gallbladder cancer.

D. gastric cancer.

E. lung cancer.

Pytanie nr 183

Nowadays the classic X-ray of the abdomen is still useful in the diagnostics of the following acute diseases of the abdomen:

- 1) perforation of the gastrointestinal tract;
- 2) bleeding into the peritoneal cavity;
- 3) ileus;
- 4) acute appendicitis;
- 5) torsion and perforation of the ovarian cyst.

The correct answer is:

A. 1,3.

B. 1,4,5.

C. 1,3,5.

D. 1,2,3,4.

E. all the above.

Pytanie nr 184

Signs and symptoms of obstructive jaundice include:

A. dark urine, high AST level, raised unconjugated bilirubin level.

B. dark urine, high ALT level, raised total bilirubin level.

C. dark urine, white stool, high ALP level.

D. high AST level, high ALT level, normal ALP level.

E. high AST level, high ALT level, raised total bilirubin level.

Pytanie nr 185

A Colles' fracture is a fracture of:

- A. femoral neck.
- B. distal epiphysis of the ulna.
- C. first metacarpal bone.
- D. distal epiphysis of the radius in the typical location.
- E. humerus of the epicondylar type.

Pytanie nr **186**

Volkman's contracture is usually observed as a complication of the fracture of:

- A. femoral bone.
- B. clavicle.
- C. radius.
- D. fibula.
- E. humerus.

Pytanie nr **187**

Which three of the listed elements constitute the so-called Virchow's triad (factors affecting blood clotting)?

- 1) slowed-down blood flow;
- 2) changes in blood composition (e.g., elevated hematocrit);
- 3) damage to the vessel wall (i.e. endothelium);
- 4) increase in the blood pressure;
- 5) increase in serum potassium level.

The correct answer is:

- A. 1,2,3.
- B. 3,4,5.
- C. 2,3,4.
- D. 1,3,5.
- E. 2,4,5.

Pytanie nr **188**

Which of the following ways of treatment restores the anti-reflux barrier in gastro-esophageal reflux disease?

- A. prokinetic drugs.
- B. proton pump inhibitors.
- C. cardiomyotomy.
- D. cardioplasty.
- E. fundoplication.

Pytanie nr **189**

Positive Homans' sign is characteristic of:

- A. acute appendicitis.
- B. inguinal hernia.
- C. calf deep vein thrombosis.
- D. Mallory-Weiss syndrome.
- E. right colon cancer.

Pytanie nr **190**

Surgical treatment of asymptomatic gallstones should be considered in the case of:

- 1) young age of the patient;
- 2) patient with diabetes mellitus;
- 3) patient who is assigned to large cardiac surgery or organ transplantation;
- 4) coexisting peptic ulcer;
- 5) clear will of the patient.

The correct answer is:

- A. 1,2,3,4.
- B. 1,2,3,5.

C. 2,3,4.

D. 1,3,4,5.

E. 1,2,3.

Pytanie nr **191**

Which of the following **is not** characteristic of Buerger's disease?

A. onset of the disease after 50 years of life.

B. habitual cigarette smoking.

C. presence of lesions in 4 limbs.

D. presence of typical lesions on the angiographic examination.

E. migratory thrombophlebitis.

Pytanie nr **192**

The gateway to the femoral hernia is the femoral ring which includes the following structures, **except for**:

A. inguinal ligament.

B. femoral vein.

C. lacunar ligament.

D. aponeurosis of the external oblique muscle.

E. branches of the pubic bone and the crest ligament that covers them.

Pytanie nr **193**

Indicate the true statements concerning bile peritonitis:

1) it results from the irritation of the peritoneum by the bile;

2) diagnostic puncture of the peritoneal cavity that shows the fluid stained with blood allows formulating the diagnosis;

3) evolution of the symptoms (their temporal regression) may resemble the perforation of the gastric ulcer;

4) if the diagnosis is confirmed, the first-line treatment is conservative, with broad-

spectrum antibiotic therapy;

5) the diagnosis is possible if there is a perforation of the gallbladder wall;

6) medical history of cholecystectomy allows excluding the diagnosis.

The correct answer is:

A. 1,2,4,5.

B. 1,3,5,6.

C. 2,5,6.

D. 1,3.

E. 1,4,5,6.

Pytanie nr 194

Pulse palpation in clinical settings is possible on the following arteries, **except for**:

A. ulnar artery.

B. dorsalis pedis artery.

C. posterior tibial artery.

D. common iliac artery.

E. pulse can be examined on all the above arteries.

Pytanie nr 195

Early gastric cancer is defined as:

A. lesion limited to the epithelium only.

B. lesion limited to the mucous membrane without metastases to lymph nodes.

C. lesion limited to the mucous membrane regardless the status of metastases to lymph nodes.

D. lesion limited to the mucous membrane and submucosa regardless the status of metastases to lymph nodes.

E. lesion limited to the mucous membrane and submucosa without metastases to lymph

nodes.

Pytanie nr **196**

Which of the following **is not** a complication of blood transfusion?

- A. fever.
- B. dyspnea.
- C. pain in the lumbar area.
- D. hemoglobinuria.
- E. decrease in bilirubin concentrations in the blood.

Pytanie nr **197**

Indicate features characterizing Crohn's disease:

- 1) lesions can occur in any part of the digestive tract;
- 2) lesions are limited only to mucosa and submucosa;
- 3) there are perianal fistulas in the course of the disease;
- 4) surgical treatment of this disease is based on the principle of conservative procedures;
- 5) extensive resection procedures are indicated in the surgical treatment of this disease.

The correct answer is:

- A. 1,2,4.
- B. 2,3,4.
- C. 2,3,5.
- D. 1,3,4.
- E. 1,2,3,4.

Pytanie nr **198**

Rest pain is classified on the Fontaine scale as:

- A. stage I.
- B. stage II.

C. stage III.

D. stage IV.

E. stage V.

Pytanie nr 199

Persistent vomiting may lead to:

A. hyperchloremia, hyperkalemia, metabolic alkalosis.

B. hypochloremia, hyperkalemia, metabolic alkalosis.

C. hypochloremia, hypokalemia, metabolic alkalosis.

D. hyperchloremia, hyperkalemia, metabolic acidosis.

E. hypochloremia, hyperkalemia, metabolic acidosis.

Pytanie nr 200

Which of the following is used in colon cancer prophylaxis in the course of familial adenomatous polyposis:

A. lipoxygenase inhibitors.

B. cyclooxygenase inhibitors.

C. high-protein diet.

D. glucocorticoids.

E. low-carbohydrate diet.

Pytanie nr 201

Mallory-Weiss syndrome means:

A. spastic esophageal spasm.

B. hepatic vein thrombosis.

C. irritable bowel syndrome.

D. haemorrhage from the ruptured mucosa in the area of the cardia.

E. thrombocythaemia after splenectomy.

Pytanie nr **202**

Which of the following procedures is used most frequently in patients subjected to emergency surgery because of a perforation in the sigmoid diverticulum?

A. left hemicolectomy.

B. Miles' operation.

C. lower anterior resection of the rectum.

D. Hartmann's operation.

E. sigmoid resection with immediate anastomosis.

Pytanie nr **203**

A 24-year-old patient diagnosed with lasting for three years ulcerative colitis reports persistent itching, chronic fatigue, weakness. The most likely cause of the reported complaints is:

A. inflammation of the gallbladder.

B. chronic pancreatitis.

C. primary sclerosing cholangitis.

D. colon cancer.

E. gastrointestinal stromal tumor.

Pytanie nr **204**

Indicate the set of features characteristic of Crohn's disease:

- 1) lesions can be observed in each part of the gastrointestinal tract;
- 2) lesions are limited to the mucosa and submucosa only;
- 3) perianal fistulas are frequently observed in the course of the disease;
- 4) surgical treatment of the disease is based on the principle of conserving surgery;
- 5) excessive resection is preferred in surgical treatment of the disease.

The correct answer is:

A. 1,2,4.

B. 1,3,4.

C. 2,3,5.

D. 2,3,4.

E. 1,3,5.

Pytanie nr 205

Classic signs and symptoms of acute cholangitis that form the Charcot's triad include:

A. Chelmonski's sign, Bloomberg's sign, jaundice.

B. epigastric pain, nausea and vomiting without relief, fever.

C. right upper quadrant abdominal pain, jaundice, fever with rigors.

D. right upper quadrant abdominal pain, signs of shock, jaundice.

E. epigastric pain, nausea and vomiting without relief, jaundice.

Pytanie nr 206

A surgeon, after consultation, stated that the patient had Courvoisier syndrome. It means:

A. there is no dullness over the liver during percussion (probable perforation of the digestive tract).

B. significant distention of the sigmoid colon - suspicion of a torsion.

C. abdominal guarding in the left lower abdomen (probable diverticulitis).

D. distended, painless gallbladder with accompanying jaundice.

E. pelvic resistance during rectal examination (outside the rectum).

Pytanie nr 207

Colon cancer most frequently is located within:

A. caecum.

B. liver and spleen flexure.

C. descending colon.

D. sigmoid.

E. rectum.

Pytanie nr **208**

Acute pancreatitis:

- 1) has a benign course in about 80% of cases;
- 2) is frequently characterized with symptoms of generalized peritonitis;
- 3) usually recurs in patients drinking alcohol regularly;
- 4) usually causes multiple organ dysfunction syndrome;
- 5) is treated conservatively in the majority of cases.

The correct answer is:

A. 1,2,3.

B. 1,3,5.

C. 2,3,4.

D. 2,4,5.

E. 3,4,5.

Pytanie nr **209**

Which of the following **is not** a possible consequence of a severe injury?

A. hypothermia.

B. hypovolemic shock.

C. coagulopathy.

D. acute respiratory failure.

E. alkalosis.

Pytanie nr **210**

Which of the following **is not** the name for inguinal hernia repair operation technique?

- A. Bassini.
- B. Halsted.
- C. Littre.
- D. Rutkow.
- E. Shouldice.

Pytanie nr **211**

Which of the following diseases **is not** associated with the presence of colon polyps?

- A. Gardner syndrome.
- B. Peutz-Jeghers-Touraine's syndrome.
- C. hereditary non-polyposis colorectal cancer (HNPCC).
- D. familial adenomatous polyposis.
- E. juvenile polyposis syndrome.

Pytanie nr **212**

A patient was admitted to the surgical ward in duty hours. The patient needs urgent surgery but he receives chronic anticoagulant therapy with vitamin K antagonist (VKA).

Which of the following should be used to reverse VKA action promptly?

- A. platelet concentrate.
- B. fresh frozen plasma.
- C. serum albumin.
- D. vitamin K intravenously.
- E. A and D are correct.

Pytanie nr **213**

Carcinoid is an epithelial neoplasm originating from the cells of the neuroendocrine system

and is usually located in:

- A.** gastrointestinal tract.
- B.** pancreas.
- C.** thyroid.
- D.** gallbladder.
- E.** adrenals.

Pytanie nr **214**

Which type of intracranial hemorrhage is caused by the injury of the middle meningeal artery?

- A.** epidural.
- B.** frontotemporal.
- C.** subdural.
- D.** intra-axial.
- E.** occipito-parietal.

Pytanie nr **215**

The patient in discharge papers has the annotation: 'Condition after Hartmann surgery'. It means that:

- A.** he underwent total colectomy with the creation of the intestinal reservoir (pouch) and protective ileostomy.
- B.** he has temporary, end-colostomy.
- C.** he has temporary, end-ileostomy.
- D.** he has permanent, end-colostomy.
- E.** he underwent a submucosal resection of haemorrhoids.

Pytanie nr **216**

Indicate the true statement concerning a hepatic hemangioma:

- A.** is asymptomatic in majority of patients and is usually revealed incidentally by imaging examination.
- B.** when diagnosed it always demands surgical treatment because of possible hemorrhagic complications.
- C.** presents most frequently with a non-specific pain localized under the right costal margin, usually occurring after the meal.
- D.** A, B are true.
- E.** B, C are true.

Pytanie nr 217

The ankle-brachial pressure index (ABPI) in healthy adults is at least 1. Its value below 0.5 indicates:

- A.** critical ischemia of the limb.
- B.** thrombosis of superficial veins.
- C.** thrombosis of deep veins.
- D.** pulmonary embolism.
- E.** such an ABPI value is not possible.

Pytanie nr 218

Sudeck's atrophy may occur as a result of:

- A.** head trauma.
- B.** gastrointestinal bleeding.
- C.** limb immobilization.
- D.** lysis of a neoplastic tumour.
- E.** heart attack.

Pytanie nr 219

Ménétrier disease is regarded as a precancerous condition of:

- A. stomach.
- B. duodenum.
- C. small intestine.
- D. colon.
- E. gallbladder.

Pytanie nr **220**

Which of the following **is not** associated with the increased risk of breast cancer?

- A. age over 35 years.
- B. regular alcohol intake.
- C. obesity.
- D. late menarche and early menopause.
- E. hormone replacement therapy including oral contraceptives.

Pytanie nr **221**

The most common malignant tumor of the thyroid is:

- A. medullary cancer.
- B. papillary cancer.
- C. follicular cancer.
- D. anaplastic cancer.
- E. signet ring cell carcinoma.

Pytanie nr **222**

This disease usually affects young smoking men. It manifests itself with pain in the feet and toes, aggravating while moving. Superficial thrombophlebitis may co-occur.

Arteriography shows occlusions and stenosis of small caliber arteries. Limb necrosis may occur in the course of the disease. The disease is not related to atherosclerosis. The above is a description of:

- A.** Raynaud's disease.
- B.** Buerger's disease.
- C.** juvenile arthritis.
- D.** Leriche syndrome.
- E.** Horton's disease.

Pytanie nr **223**

Which stage of lower limb ischemia in the Fontaine classification is characterized with intermittent claudication?

- A.** I.
- B.** II.
- C.** III.
- D.** IV.
- E.** V.

Pytanie nr **224**

The characteristic feature of Leriche syndrome is:

- A.** occlusion of both femoral arteries.
- B.** occlusion of both mesenteric arteries (superior and inferior).
- C.** occlusion of both common carotid arteries.
- D.** occlusion of the distal part of the abdominal aorta or both common iliac arteries.
- E.** occlusion of both renal arteries.

Pytanie nr **225**

The second most common thyroid cancer is:

- A.** papillary cancer.
- B.** anaplastic cancer.
- C.** follicular cancer.
- D.** medullary cancer.
- E.** giant cell tumor.

Pytanie nr **226**

Thromboangiitis obliterans is also known as:

- A.** Takayasu's disease.
- B.** Riley-Smith syndrome.
- C.** Buerger disease.
- D.** Sturge-Weber syndrome.
- E.** Klippel-Trénaunay syndrome.

Pytanie nr **227**

In the classification of upper gastrointestinal hemorrhage according to Forrest grade I denotes:

- A.** recent hemorrhage.
- B.** active hemorrhage.
- C.** old hemorrhage.
- D.** no sign of hemorrhage.
- E.** Forrest classification does not refer to gastrointestinal hemorrhage.

Pytanie nr **228**

Which of the following colon lesions bears the highest risk of malignant transformation?

A. tubulovillous adenoma.

B. tubular adenoma.

C. villous adenoma.

D. hyperplastic polyp.

E. juvenile polyp.

Pytanie nr **229**

Which of the following signs **is not** typical of acute appendicitis?

A. Dunphy's sign.

B. Blumberg sign.

C. psoas sign.

D. lack of appetite.

E. Cullen's sign.

Pytanie nr **230**

The symptoms of Whipple's triad comprise:

1) consciousness disorders;

2) hypoglycaemia;

3) hyperglycaemia;

4) disappearance of symptoms after intravenous glucose administration;

5) gallstones.

The correct answer is:

A. 1,2,4.

B. 1,3,5.

C. 2,4,5.

D. 1,2,5.

E. 1,2,3.

Pytanie nr **231**

Ogilvie syndrome is:

- A.** inherited lack of colon autonomic innervations.
- B.** acute pseudo-obstructive large bowel dilatation.
- C.** mechanical large bowel obstruction.
- D.** hereditary non-polyposis colon cancer.
- E.** ruptures of a ventral part of the oesophageal mucosa caused by vomiting.

Pytanie nr **232**

Which of the following is the most common malignant tumor found in the liver?

- A.** hepatocellular carcinoma (HCC).
- B.** cholangiocarcinoma (CCC).
- C.** focal nodular hyperplasia (FNH).
- D.** colon cancer metastasis.
- E.** cystadenocarcinoma.

Pytanie nr **233**

Indicate **the false** statement concerning erysipelas:

- A.** it is an infectious disease caused by staphylococci.
- B.** infection may spread by the lymphatic system (so-called erysipelas migrans).
- C.** onset is acute and the symptoms rapidly develop.
- D.** high doses of benzylpenicillin are a treatment of choice.
- E.** lesions are usually located on lower limbs or the face, skin necrosis and gangrene occur in some cases.

Pytanie nr **234**

The Lauren classification concerns:

- A. colon cancer.
- B. gastric cancer.
- C. pancreatic cancer.
- D. liver cancer.
- E. extent of inflammation lesions in the stomach.

Pytanie nr **235**

Which of the following is called Ogilvie syndrome?

- A. jaundice in the course of pancreatic head cancer.
- B. paralytic ileus in porphyria.
- C. colonic pseudo-obstruction without any mechanical obstruction.
- D. tumor of the porta hepatis that causes jaundice.
- E. none of the above.

Pytanie nr **236**

Indicate **the false** statement concerning the Whipple's triad:

- A. consciousness disturbances related to fasting are present.
- B. patient is usually lean.
- C. hypoglycemia below 2.22 mmol/L (40 mg/dL) may be observed.
- D. symptoms subside after intravenous glucose administration.
- E. it is related to a pancreatic neuroendocrine tumor.

Pytanie nr **237**

Positive Chvostek, Trousseau and Erb's signs suggest:

- A. acute cholecystitis.

- B. acute pancreatitis.
- C. hyperthyroidism.
- D. adrenocortical hyperfunction.
- E. hypoparathyroidism.

Pytanie nr **238**

Linitis plastica denotes:

- A. cancer extensively infiltrating the gastric wall that gives early metastases to lymph nodes.
- B. colon cancer causing ileus in the lower gastrointestinal tract.
- C. esophageal cancer that turns the esophagus into a hard, rigid tube.
- D. advanced, non-resectable pancreatic cancer.
- E. rare, primary hepatic cancer.

Pytanie nr **239**

Klatskin tumor is a term given to:

- A. gallbladder cancer.
- B. cancer of the ampulla of Vater.
- C. hepatocellular carcinoma originating in a cirrhotic liver affected by hepatitis type B.
- D. cholangiocarcinoma.
- E. pancreatic cancer in the head of the pancreas.

Pytanie nr **240**

A 68-year-old patient, previously in good health, who has not needed medical attention for the last year, is referred to the surgical outpatient clinic because of a yellowish shade of his skin observed for 7 days. The physical examination shows the enlarged non-painful gallbladder. Which of the following is the most probable diagnosis?

- A. primary biliary cirrhosis.
- B. primary sclerosing cholangitis.
- C. acute cholecystitis.
- D. acute cholangitis.
- E. pancreatic cancer in the head of the pancreas.

Pytanie nr **241**

Which of the following concerning adrenal glands is true?

- 1) incidentaloma always requires surgery;
- 2) ultrasound is the test of choice in the imaging diagnostics of adrenal glands;
- 3) laparoscopy should not be used in the surgical treatment of adrenal tumors;
- 4) pheochromocytoma develops from cells of the adrenal cortex;
- 5) Conn syndrome most often is associated with benign adenoma of the glomerular layer of the adrenal gland.

The correct answer is:

- A. 1,3.
- B. 2,3.
- C. 2,4,5.
- D. only 1.
- E. only 5.

Pytanie nr **242**

A frequent complication after abdominal surgery is urinary retention. The symptoms include pain within the hypogastric region and excessive filling of the bladder along with inability to initiate micturition. The appropriate treatment procedures of postoperative urinary retention should start with:

- A. rapid intravenous infusion of 1000 ml normal saline (0.9% NaCl) and then 40 mg oral furosemide.
- B. urinary tract catheterization for 2-3 days.
- C. nephrostomy.

D. oral tamsulosin (rec. α_1 antagonist) until normal diuresis.

E. haemodialysis, since post-operative urinary retention is always due to acute kidney failure.

Pytanie nr **243**

In acute pancreatitis, the indications for initiating antibiotic therapy include:

- 1) any case of acute pancreatitis related to choledocholithiasis;
- 2) any case of alcohol-related acute pancreatitis;
- 3) confirmed presence of infected necrosis in the course of acute pancreatitis;
- 4) pancreatic pseudocysts as a complication in acute pancreatitis.

The correct answer is:

A. 1,3,4.

B. 2,3,4.

C. 2,4.

D. 3 only.

E. 4 only.

Pytanie nr **244**

After falling from the height of 5 m, the patient:

- opens eyes after pain stimulus;
- is confused and disoriented, cannot tell where he is or what happened;
- does not obey commands to make a movement but can localize painful stimulus;

In the GCS, the patient will score:

A. 15 points.

B. 13 points.

C. 12 points.

D. 11 points.

E. 10 points.

Pytanie nr **245**

The indication for splenectomy can be:

- A. hereditary spherocytosis.
- B. idiopathic thrombocytopenia.
- C. thalassemia.
- D. sickle cell anaemia.
- E. all of the above.

Pytanie nr **246**

An 83-year-old male who was treated for arrhythmia and arterial hypertension was admitted to emergency dept. due to severe abdominal pain. The pain appeared suddenly, about an hour before admission, was at first located within the epigastric region and was paroxysmal in nature. However, at the time of examination, the pain is continuous and concerns the entire abdomen area. The abdomen is bloated, and positive peritoneal symptoms are present in all abdominal quadrants. The patient has nausea and vomits with the stomach content. Peristalsis cannot be heard. Physical examination shows large inguinal hernia on the right side, and per rectum examination, brown stool in the rectal ampulla. HR: 96/min, BP: 103/57 mmHg, RR: 18/min, WBC: 33000/mm³, Hgb: 11.2 g/dl, Hct: 31%, Amylase: 140 U/l, D-dimers 15000 µg/l, Tnl: <0.001 ng/ml. ECG: without abnormalities. Indicate what is the cause of the patient's complaints:

- A. gastric ulcer perforation.
- B. acute intestinal ischaemia.
- C. myocardial infarction.
- D. obstruction caused by colon tumour.
- E. acute pancreatitis.

Pytanie nr **247**

A 53-year-old male checked into emergency dept. due to painfulness within the right hypochondriac region. The pain, which appeared the day before, is paroxysmal and accompanied by nausea and vomiting. At present, the patient has fever with chills, 39.2 degrees Celsius. He also reports dark-coloured urine. On physical examination, Chelmonski symptom is positive, and yellowing of the eye sclera can be observed. Per

rectum, the stool in the rectal ampulla is discoloured. Laboratory findings: Hgb 12.5 g/dl, Hct 36%, CRP 120 mg/l, bilirubin 80 µmol/l (4.68 mg/dl). Ultrasound examination shows a common bile duct of 11 mm in diameter and a thin-wall gallbladder with numerous deposits. Indicate the right diagnosis and procedure:

- A.** acute cholecystitis - laparoscopic cholecystectomy and antibiotic therapy.
- B.** cholangitis - oral conservative treatment with antibiotics.
- C.** cholangitis - endoscopic retrograde cholangiopancreatography and antibiotic therapy.
- D.** acute cholecystitis - oral conservative treatment with antibiotics.
- E.** diagnosis cannot be made based on the information provided; all diagnoses are equally probable.

Pytanie nr 248

Indicate the **false** statement regarding venous ulcers of lower extremities:

- A.** the risk factors for venous ulcerations include previous deep vein thrombosis, thrombophilia and varicose veins.
- B.** venous ulcers occur on the lower legs, typically around the lateral or medial ankle area.
- C.** venous ulcers are characterised by severe pain which can be relieved by unweighting the leg.
- D.** the skin surrounding venous ulcers is usually atrophic, can be discoloured, and the limb is often swollen.
- E.** all the above statements are true.

Pytanie nr 249

The complications of diverticular disease include:

- A.** sigmoid cancer.
- B.** sigmoidovesical fistula.
- C.** ulcerative colitis.
- D.** left-sided renal colic.

E. left ovarian cyst.

Pytanie nr **250**

Indicate true statements regarding an abscess:

- 1) an essential treatment is its evacuation;
- 2) surgery is contraindicated; antibiotic therapy is more beneficial;
- 3) the complication of perirectal abscess can be an perianal fistula;
- 4) the complication of perirectal abscess can be an anal fissure;
- 5) peritoneal abscess is more commonly found among males.

The correct answer is:

A. 1,2,4.

B. 1,3,5.

C. 2,3,5.

D. 2,3,4.

E. 1,3,4.

Pytanie nr **251**

The most frequent cause of hyperthyroidism is:

A. Graves' disease.

B. single thyroid adenoma.

C. multiple thyroid adenomas.

D. exogenous thyroid hormone overdose.

E. differentiated thyroid cancer.

Pytanie nr **252**

Whipple's procedure refers to:

A. pancreaticoduodenectomy.

B. pancreaticoduodenectomy along with cholecystectomy.

- C. resection of the pancreas tail.
- D. pancreatogastrectomy.
- E. peripheral pancreatectomy and splenectomy.

Pytanie nr **253**

The development of the gallbladder empyema may be due to:

- A. delayed surgery for acute cholecystitis.
- B. prolonged entrapment of the stone in the neck of the gallbladder.
- C. previous cholecystocele.
- D. gallbladder cancer.
- E. all of the above.

Pytanie nr **254**

The most prevalent colon polyps include:

- A. tubular adenomas.
- B. villous adenomas.
- C. tubulovillous adenomas.
- D. inflammatory polyps.
- E. hyperplastic polyps.

Pytanie nr **255**

Assessment of the patient's nutritional status helps prepare him/her for surgical treatment through introduction of a scheduled nutritional therapy. Indicate the parameter which **is not** used for classifying the patient as malnourished:

- A. body mass index (BMI) < 18.5.
- B. body mass loss (ratio between present body mass and that before the disease) of less than 10%.

C. albumin concentration < 3.5 g/dl.

D. clinical symptoms: weakness, loss of fat and muscle mass.

E. low body mass at present.

Pytanie nr **256**

Which of these medical conditions should be considered in the differentiation of acute cholecystitis?

1) gastric or duodenal ulcer perforation;

2) sigmoid diverticulitis;

3) cholangitis;

4) acute pancreatitis;

5) mechanical obstruction.

The correct answer is:

A. 1,2,5.

B. 1,3,5.

C. 2,3,5.

D. 2,3,4.

E. 1,3,4.

Pytanie nr **257**

Indicate true statements regarding incidentaloma:

1) it is an incidentally found tumour-like lesion, most often located in adrenal glands;

2) it is always an indication for surgery;

3) after detecting adrenal incidentaloma, it is always necessary to verify its potential hormonal activity;

4) the most relevant imaging diagnostics to verify the adrenal tumour is CT;

5) if the tumour is large (above 5 cm), the patient should be classified for urgent surgery, regardless of whether or not hormonal activity of the tumour was assessed.

The correct answer is:

A. 1,2,5.

B. 1,3,5.

C. 2,3,5.

D. 1,3,4.

E. 2,4,5.

Pytanie nr **258**

Indicate the procedures that should be carried out at the emergency dept. when taking care of a patient diagnosed with the perforation of the peptic ulcer (of stomach or duodenum):

- 1) insert a nasogastric tube to reduce the volume of gastric contents which may be discharged from the stomach to the peritoneal cavity;
- 2) insert Sengstaken-Blakemore tube to close the perforation in the stomach;
- 3) perform standing X-ray of the abdomen to confirm the diagnosis;
- 4) perform gastroscopy to confirm the diagnosis;
- 5) replenish fluids and electrolytes.

The correct answer is:

A. 1,2,5.

B. 1,3,5.

C. 2,3,5.

D. 2,4,5.

E. 1,3,4.

Pytanie nr **259**

The inflammatory process within the nail fold, which is usually purulent, applies to:

A. paronychia.

B. felon.

C. paraphimosis.

D. boil.

E. gangrene.

Pytanie nr **260**

A 56-year-old male patient diagnosed with adenocarcinoma of the body of the stomach, confirmed by histopathological findings, came to see a doctor at an outpatient clinic. Which examination will you order for the local staging assessment of the cancer:

- A. abdominal ultrasound.
- B. diagnostic laparoscopy.
- C. paracentesis.
- D. abdominal CT.
- E. PET.

Pytanie nr **261**

A 70-year-old female patient with a history of rectal cancer surgery three years before, came in to an outpatient clinic. She provided the findings of the last two CEA blood tests. The first one showed 8.45 ng/ml, and the other one, performed three months afterwards, 19.39 ng/ml (normal range <5.0 ng/ml). The dual-phase abdominal and thoracic CT scan and colonoscopy findings did not show any abnormalities. Indicate which examination should be ordered for the patient:

- A. transrectal ultrasound.
- B. pelvic magnetic resonance imaging (MRI).
- C. PET-CT.
- D. diagnostic laparoscopy.
- E. CEA test in three months' time.

Pytanie nr **262**

A 34-year-old female patient who has been treated for paroxysmal hypertension for three years came to see a doctor at an outpatient clinic. She complains of polydipsia, profuse sweating and heart palpitations. Laboratory tests showed considerably increased blood catecholamines, and double-phase abdominal CT scan showed a 3 cm tumour in the left adrenal gland. Indicate appropriate treatment:

- A. resection of adrenal gland with the tumour.
- B. fine-needle aspiration biopsy of the tumour.

- C. abdominal magnetic resonance (MRI).
- D. tumour resection with adrenal gland preservation.
- E. bilateral adrenalectomy.

Pytanie nr **263**

The factors that increase the risk for pancreatic cancer **do not** include:

- A. obesity.
- B. insulin-dependent diabetes mellitus.
- C. chronic exposure to aluminum.
- D. tobacco smoking.
- E. acute pancreatitis.

Pytanie nr **264**

A pre-operative local staging assessment of rectal adenocarcinoma, considered to be a gold standard examination, is performed using:

- A. transrectal ultrasound.
- B. double-phase abdominal and pelvic CT.
- C. pelvic magnetic resonance (MRI).
- D. proctosigmoidoscopy.
- E. abdominal and pelvic PET-CT.

Pytanie nr **265**

Indicate true statement(s) regarding pancreatic adenocarcinoma:

- 1) it usually derives from acinic cell of the pancreas;
- 2) Whipple surgery is the method of choice for resection of the head of the pancreas;
- 3) migrating phlebotrombosis may develop in the course of the disease;
- 4) it can stem from the intraductal papillary mucinous neoplasm of the pancreas (IPMN);
- 5) the Courvoisier symptom is characteristic of cancer of the body of the pancreas.

The correct answer is:

- A. 1,2,4.
- B. 2,5.
- C. 2,3,4.
- D. 1,3,4,5.
- E. 2 only.

Pytanie nr **266**

In a young woman of reproductive age, the histopathological findings from fine-needle aspiration biopsy of the abdominal wall revealed a desmoid tumour. Indicate the best treatment option:

- A. tumour resection along with a broad margin of healthy tissue.
- B. observation and re-examination.
- C. resection confined to the tumour.
- D. taking a tissue specimen during open incisional biopsy.
- E. tumour resection along with a narrow margin of healthy tissue.

Pytanie nr **267**

In young women of reproductive age, a fibrous tumour of the abdominal wall, which is comorbid with the Gardner's syndrome, will most probably be:

- A. *fibrosarcoma*.
- B. *peritoneal mesothelioma*.
- C. old fibrotic haematoma.
- D. irreducible hernia.
- E. *desmoid*.

Pytanie nr **268**

An elderly male patient with obstructive lung disease was diagnosed with hernia. It was protruding from the abdominal cavity through the transverse fascia which forms the posterior wall of the inguinal canal, at the site bordering the conjoint tendon at the top, the inguinal ligament at the bottom, and laterally, through inferior epigastric vessels. The hernia in such location is known as:

A. oblique inguinal hernia.

B. scrotal hernia.

C. direct inguinal hernia.

D. femoral hernia.

E. spigelian hernia.