

Nr 1. Choose the correct answer concerning acquired pellicle:

- A. it is composed of glycoproteins, fructans and glucans.
- B. it is cell-free layer of precipitated salivary protein material such as glycoproteins, phosphoproteins and lipids and its thickness is about 0,01-10 µm.
- C. it does not modify carie initiation.
- D. it contains glycoproteins, phosphoproteins and bacteria: *S. mutans*, *S. sanguis* and *S. mitis*.
- E. it does not protect teeth from abrasion, attrition and erosion.

Nr 2. When may antibiotic therapy be indicated when we perform endodontic treatment of non-vital teeth?

- A. as prophylaxis for medically compromised patients with endocarditis and congenital heart diseases.
- B. as prophylaxis for patients with diabetes mellitus.
- C. when we perform endodontic treatment of the teeth with acute apical periodontitis with symptoms like periapical abscess, pain, high temperature and lymphadenopathy.
- D. when we perform endodontic treatment of the teeth with acute apical periodontitis and drainage through root canal is not possible.
- E. all of the above are correct.

Nr 3. 43 years old patient complained of severe pain of mandibular first right premolar. The tooth was sensitive to percussion, was not sensitive to electric pulp test nor cold test. There was no swelling of the soft tissues. Periapical radiograph showed no pathology. The **most probable** diagnosis is:

- A. reversible pulpitis.
- B. acute apical abscess.
- C. chronic apical periodontitis.
- D. condensing osteitis.
- E. periapical granuloma.

Nr 4. Choose **false** sentence concerning tertiary dentin:

- A. it is formed as a reaction for external irritants such as attrition, abrasion, trauma, moderate-rate caries and some operative procedures.
- B. it is formed by replacement of odontoblasts in response to moderate level irritants.
- C. it usually appears as a localized dentin deposit on the wall of the pulp cavity immediately subadjacent to the area of the tooth that has received the injury.
- D. it is called reparative dentin.
- E. it contains more tubules comparing to primary dentin.

Nr 5. Which methods may be used for an early carie diagnosis?

- 1) visual methods; 2) laser Yag-Nd; 3) transillumination; 4) radiography.

The correct answer is:

- A. only 1 and 3. B. only 1. C. only 2 and 3. D. 1,3 and 4. E. all of the above.

Nr 6. Choose the true sentence concerning root carious lesions:

- A. they have less defined margins comparing to enamel caries.
- B. they progress not as rapidly as enamel caries.
- C. they are classified into four stages according to Dean.
- D. stages 1,2 and 3 are reversible.
- E. arrested root carious lesions should always be restored with composite materials.

Nr 7. Which sentences concerning arrested caries are true?

- 1) they are caries within the enamel without progression;
- 2) they are a type of chronic caries;
- 3) they develop in the presence of the fluoride ions that are penetrating the enamel after changing the oral environment when caries of enamel are present;
- 4) the enamel within these lesions is more susceptible to further carie attack.

The correct answer is:

- A. 1 and 2. B. only 1. C. 1,2 and 3. D. 1 and 3. E. all of the above.

Nr 8. Which of the following **is not** a basis for classifying carious lesions?

- A. etiology.
- B. location.
- C. complexity.
- D. progress of decay.
- E. extent of caries.

Nr 9. While enlarging a root canal we may use chelating agents. Which statement concerning their use is **false**?

- A. EDTA is ethylenediaminetetractic acid.
- B. EDTA may be used to eliminate many cleaning and shaping frustrations.
- C. the purpose for the use of a chelator is lubrication, emulsification and holding debris in suspension.
- D. chelators can be used in either a viscous suspension or an aqueous solution.
- E. while using EDTA solution there is a risk of oedema.

Nr 10. A pulp polyp in the lower first permanent molar is an example of:

- A. pulp necrosis.
- B. hyperplastic pulpitis.
- C. reversible pulpitis.
- D. irreversible pulpitis with nonvital pulp.
- E. a response to carious exposure of the pulp when the pulp becomes necrotic.

Nr 11. Choose the **false** sentence concerning calcium hydroxide therapy in root canal treatment:

- A. calcium hydroxide dressings are therapeutic in the prevention or treatment of flare-ups.
- B. the possibility of reducing postoperative pain may depend on its ability to kill bacteria and neutralize their by-products.
- C. researchers attribute the soft tissue dissolving potential and antibacterial effect of calcium hydroxide to its high pH.
- D. the placement of calcium hydroxide between appointments is recommended for all teeth, especially during long interappointment delays and when periapical infection is present.
- E. calcium hydroxide is not an effective intracanal medication when it is mixed with chlorhexidine gluconate or iodine potassium iodide.

Nr 12. In order to disclose dental plaque one may use:

A. Plaque-Test. **B.** Broxo-Test. **C.** Erythrosin. **D.** only A and B. **E.** all of the above.

Nr 13. Which of the listed carbohydrates has the lowest cariogenic potential?

A. sucrose. **B.** glucose. **C.** fructose. **D.** lactose. **E.** starch.

Nr 14. A toxic dose of fluoride per kg of adult body mass is at least:

A. 0,5 mg. **B.** 2 mg. **C.** 5 mg. **D.** 7 mg. **E.** 10 mg.

Nr 15. Match noncarious lesions with their definitions:

- | | |
|------------------|--|
| 1) abrasion | a) mechanical tooth wear – tooth to tooth; |
| 2) demastication | b) mechanical wear due to flexion forces caused by excentric occlusal loading; |
| 3) attrition | c) interaction of food and teeth; |
| 4) abfraction | d) chemical dissolving of tooth tissues; |
| 5) erosion | e) biological degeneration; |
| 6) resorption | f) mechanical tooth loss due to physical wear from external agents. |

The correct answer is:

- | | |
|------------------------------|------------------------------|
| A. 1e,2d,3b,4a,5c,6f. | D. 1f,2c,3a,4b,5d,6e. |
| B. 1c,2a,3b,4d,5f,6e. | E. 1f,2b,3c,4a,5d,6e. |
| C. 1a,2b,3c,4d,5e,6f. | |

Nr 16. Indicate **the most important** anaerobic bacteria responsible for periapical lesion formation:

- A.** *Lactobacillus*, *Streptococcus mutans*.
B. *Actinomyces*, *Lactobacillus*, *Eubacterium*.
C. *Eubacterium*, *Bacteroides*, *Streptococcus mutans*.
D. *Peptostreptococcus*, *Actinomyces*, *Lactobacillus*.
E. *Bacteroides*, *Peptostreptococcus*, *Eubacterium*, *Actinomyces*.

Nr 17. 40 years old patient came to a dental office because he had noticed prominence near left maxillary premolar. Clinical examination revealed that pus exudate was flowing out of this prominence on the oral mucosa. The periapical radiograph showed translucency near the tooth 24. There were no symptoms like pain, and vitality tests were negative. What is the diagnosis?

- | | |
|-----------------------------------|---------------------------------------|
| A. periapical granuloma. | D. acute apical periodontitis. |
| B. chronic apical abscess. | E. condensing osteitis. |
| C. acute apical abscess. | |

Nr 18. Indicate a non-chelating agent from those listed below:

A. RC-Prep. **B.** Chlorhexidin. **C.** File-Eze. **D.** Endogel. **E.** Largal Ultra.

Nr 25. Chlorhexidine is used in caries prevention as an added measure in cases of reduced salivary flow. Indicate on which of the listed mechanisms the action of chlorhexidine is based.

- A. enhancing remineralization.
- B. improving the buffering of the pH.
- C. antiseptic, prevention of bacterial adherence.
- D. agglutinating bacterial cells to form large complexes which can be easily eliminated.
- E. increasing saliva production by parotid gland stimulation.

Nr 26. A 27-year-old male patient comes to a dental office in the morning; his main complaint is pain lasting since yesterday afternoon, localised in the region of the tooth 36 and 37. He also feels a little swelling in this region, malaise and high temperature. During intraoral examination both teeth were tender to pressure, in pulp tests of 36 – no response. On the X-ray only the widening of the periodontal space of 36 was found. The most probable diagnosis is:

- A. acute irreversible pulpitis.
- B. acute periapical abscess.
- C. chronic apical periodontitis.
- D. chronic irreversible pulpitis.
- E. chronic apical abscess.

Nr 27. From the list of symptoms choose those that can be observed in acute irreversible pulpitis:

- 1) spontaneous pain lasting for 5 days;
- 2) severe pain to thermal stimuli;
- 3) pain on percussion;
- 4) no response to thermal stimuli.

The correct answer is:

- A. only 1.
- B. only 2.
- C. 1 and 2.
- D. 1,2 and 3.
- E. 3 and 4.

Nr 28. From the list of symptoms choose those that can be observed in reversible pulpitis:

- 1) spontaneous pain;
- 2) severe pain to thermal stimuli;
- 3) pain on percussion;
- 4) no response to thermal stimuli.

Correct answer:

- A. only 1.
- B. only 2.
- C. only 4.
- D. 3 and 4.
- E. none of the above.

Nr 29. A patient (aged 18) shows up after having a bicycle accident. On the x-ray you notice horizontal root fracture localized in the apical third of 11. During pulp vitality testing there was no response. The tooth was splinted. What are the next steps in the treatment during the following 2 weeks?

- A. treatment is completed.
- B. vitality pulp tests should be performed during the following weeks after the injury.
- C. pulp removal and calcium hydroxide placement into the canal.
- D. pulp removal and obturation.
- E. pulp removal and antibiotic – steroid dressing placement into the canal.

Nr 30. A soft polyp-like outgrowth is seen in an extensive carious lesion in the tooth 4.6, in a youngster. Though the tooth is not painful at present, the patient remembers several incidents of spontaneous pain some time ago. The most likely diagnosis is:

- A. pulpal necrosis.
- B. pulp calcification.
- C. internal resorption.
- D. chronic hyperplastic pulpitis.
- E. acute irreversible pulpitis.

Nr 31. A soft, reddish polyp-like outgrowth is seen in an extensive carious lesion in the tooth 4.6, in a youngster. Though the tooth is not painful at present, the patient remembers several incidents of spontaneous pain some time ago. What kind of therapy is the best in this case?

- A. pulp removal after anesthesia application.
- B. the removal of necrotic pulp (anesthesia is not necessary).
- C. the extraction of the tooth is the only possibility.
- D. temporary restoration – ZOE.
- E. the removal of the overgrown tissue and calcium hydroxide placement on the pulp in the canals.

Nr 32. What are the possible complications of a traumatic injury of a tooth?

- A. internal resorption.
- B. calcific metamorphosis.
- C. tooth discoloration.
- D. pulp necrosis.
- E. all of the above.

Nr 33. Teeth after endodontic treatment often become discolored. Which is **the most likely** factor responsible for the discoloration?

- A. microleakage under the resin composite restoration.
- B. a tetracycline overdose during the treatment.
- C. pulp remnants in the crown.
- D. antibiotics used as a canal dressing during visits.
- E. calcium hydroxide intracanal use.

Nr 34. Tetracycline discoloration is an example of:

- A. extrinsic and generalized discoloration.
- B. intrinsic discoloration due to hereditary disorders.
- C. intrinsic and generalized discoloration.
- D. extrinsic and localized discoloration.
- E. discoloration due to changes in superficial structures of enamel.

Nr 35. The method of obturation for canals with internal resorptive defects should be chosen very carefully. Which of the methods below do you consider **the best**?

- A. lateral condensation.
- B. solvent-softened custom cones.
- C. thermomechanical vertical condensation.
- D. single cone.
- E. sealer only.

Nr 36. The heat produced during the preparation can be one of the iatrogenic factors influencing the health of the pulp. Indicate the factors that can modify the irritating effect of the heat:

- 1) the thickness of remaining dentin;
- 2) cutting time;
- 3) the type of material from which burs are manufactured;
- 4) the sharpness of burs.

The correct answer is:

- A.** only 1. **B.** only 2. **C.** 3 and 4. **D.** 2,3 and 4. **E.** all of the above.

Nr 37. In bulimic patients the erosion of the teeth develops due to:

- A.** enzymatic action. **D.** hereditary disorder.
B. acidic action. **E.** soft toothbrush use.
C. bacterial action.

Nr 38. On which teeth surfaces does erosion occur in bulimic patients:

- A.** the lingual surfaces of lower anteriors.
B. the facial and buccal surfaces of upper teeth.
C. the palatal and occlusal surfaces of all maxillary teeth and the buccal and occlusal surfaces of mandibular teeth.
D. the lingual surfaces of mandibular teeth.
E. all teeth surfaces.

Nr 39. Which of the following manifestations is the most probable side effect of bleaching agents used for vital bleaching?

- A.** pulpitis. **D.** tooth hypersensitivity.
B. gingival recession. **E.** candidiasis.
C. demineralization.

Nr 40. Which of the following canals in maxillary first molar is usually the most difficult to locate and prepare?

- A.** palatal. **D.** all of the canals are relatively easy to find.
B. mesiobuccal. **E.** both mesiobuccal and palatal are relatively difficult to find.
C. distobuccal.

Nr 41. What instruments can be used for enlarging root canal orifices?

- 1) Gates-Glidden drills;
- 2) Peeso Reamers;
- 3) barbed broaches;
- 4) Nickel-Titanium files

The correct answer is:

- A.** all of the above. **B.** 1 and 2. **C.** only 1. **D.** 1 and 4. **E.** only 4.

Nr 42. Choose typical symptoms of chronic apical abscess:

- 1) the presence of sinus tract;
- 2) chronic abscess may drain through periodontium into the sulcus and may resemble periodontal abscess or pocket;
- 3) there is usually a swollen cheek or lip and the tooth is painful;
- 4) because of existing drainage chronic abscess is usually asymptomatic unless occasional closure of the sinus pathway occurs, which can cause exacerbation;
- 5) radiographic features of only periodontal ligament space are thickening.

The correct answer is:

- A.** 1,2,3,4. **B.** 1,2,3. **C.** 1,2,4. **D.** 1,2,5. **E.** 1,5.

Nr 43. Indicate the false statement about gutta-percha cones:

- A.** more than half of their content is zinc oxide, which provides radiopacity of gutta-percha.
B. they lack the adhering quality.
C. they can be disinfected and sterilised using 5% NaOCl.
D. Gutta-percha cones soften at a temperature above 64-65°C.
E. the size and taper standards for gutta-percha cones are less stringent than for endodontic instruments, with tolerance up to 0.04-0.05 mm.

Nr 44. Choose from the following sentences one which is true about pulp stones (denticles):

- A.** false pulp stones contain tubules.
B. true pulp stones are composed of concentric layers of calcified material with no tubular structure.
C. according to their location in the pulp stones may be described as free, adherent and interstitial.
D. large denticles may be recognized on radiographs; they never cause symptoms or pain.
E. their presence is not influencing either restorative or endodontic treatment.

Nr 45. Choose factors from the list below which may play role in the etiology of leukoplakia:

- A.** tobacco smoking only. **D.** alcohol drinking.
B. iron deficiency. **E.** the etiology is multifactorial; all of the above may be involved.
C. vitamin deficiencies.

Nr 46. Which of the listed conditions **is not** a premalignant one?

- A.** leukoplakia. **D.** *osteogenesis imperfecta*.
B. erythroplakia. **E.** oral epithelial atrophy occurring in syphilis.
C. *lichen planus*.

Nr 47. The gingiva of the maxillary anterior teeth of a 9-year-old patient is red, edematous and bleeds easily. The remaining gingiva is normal. This condition is most likely due to:

- A.** occlusal trauma. **D.** pubertal gingivitis.
B. mouth breathing. **E.** allergy to a dentifrice.
C. vitamin C deficiency.

Nr 48. Hyperkeratosis of palms and soles, early inflammatory destruction of periodontium that leads to exfoliation of the teeth are characteristic of:

- A. Papillon-Lefevre syndrome.
- B. hypophosphatasia.
- C. Down syndrome.
- D. leukocyte adhesion deficiency.
- E. histiocytosis X.

Nr 49. Drug-influenced gingival enlargement has been observed in the patients taking:

- A. phenytoin.
- B. cyclosporin A.
- C. calcium channel blockers.
- D. phenytoin, cyclosporin A.
- E. phenytoin, cyclosporin A, calcium channel blockers.

Nr 50. Which of the following is the normal (most often observed) pattern of the eruption of primary teeth?

- A. maxillary central incisors erupt before mandibular central incisors.
- B. maxillary canines erupt before maxillary lateral incisors.
- C. maxillary first molars erupt before maxillary canines.
- D. mandibular canines erupt before mandibular first molars.
- E. mandibular second molars erupt before mandibular first molars.

Nr 51. The maxillary permanent central incisors erupt most often at the years of age:

- A. 5.
- B. 6.
- C. 7.
- D. 9.
- E. 10.

Nr 52. An overdeveloped palatal cusp in anterior maxillary teeth is called:

- A. an enamel pearl.
- B. a talon cusp.
- C. a Carabelli cusp.
- D. a supernumerary tooth.
- E. Turner's tooth.

Nr 53. White opacities in different places of enamel are a manifestation of:

- A. vitamin C deficiency.
- B. foetal erythroblastosis.
- C. acute fluoride intoxication.
- D. congenital porphyria.
- E. chronic fluoride toxicity.

Nr 54. The systemic fluoride application method does NOT mean the use of:

- A. fluoridated drinking water.
- B. fluoridated table salt.
- C. fluoride tablets.
- D. fluoride varnish.
- E. fluoridated milk.

Nr 55. A patient presents hypodontia, conical teeth, fine scanty fair hair, and heat intolerance. The **most likely** diagnosis is:

- A. achondroplasia.
- B. malignant hyperthermia.
- C. ectodermal dysplasia.
- D. amelogenesis imperfecta.
- E. cystic fibrosis.

Nr 56. Multiple supernumerary teeth are most commonly found in the patients suffering from:

- A. cherubism.
- B. ectodermal dysplasia.
- C. hypothyroidism.
- D. cleidocranial dysplasia.
- E. Down's syndrome.

Nr 57. A primary tooth injury can result in disturbances in permanent tooth development. These include all of the following **except**:

- A. enamel discoloration and hypoplasia.
- B. crown dilaceration.
- C. the arrest of root formation.
- D. the formation of Carabelli cusp.
- E. root angulation.

Nr 58. A single hypoplastic enamel defect located on the labial surface of a maxillary permanent central incisor is **most likely** due to:

- A. dietary deficiency.
- B. endocrine disturbances.
- C. tetracycline therapy.
- D. trauma to the maxillary primary central incisor.
- E. excessive fluoride intake.

Nr 59. Which of the following statements is **false**?

- A. concussion is an injury to the tooth-supporting structures without abnormal loosening or displacement of the tooth.
- B. subluxation is an injury to the tooth-supporting structures with abnormal loosening and displacement of the tooth.
- C. concussion is an injury of the tooth-supporting structures characterized by marked tenderness to percussion.
- D. enamel infraction is an incomplete fracture of the enamel without the loss of tooth substance.
- E. an enamel fracture is the loss of tooth substance confined to enamel.

Nr 60. A 4-year-old child has a normal complement of deciduous teeth, but in appearance they are bluish-brown and exhibit extensive occlusal and incisal wear. Radiographic examination indicates the obliteration of the pulp chambers. This signs are typical of:

- A. cleidocranial dysplasia.
- B. amelogenesis imperfecta.
- C. histiocytosis X.
- D. erythroblastosis fetalis.
- E. dentinogenesis imperfecta.

Nr 61. Which of the following statements related to double tooth formations is **false**?

- A. in contrast to other dental anomalies they appear more frequently in primary dentition.
- B. they are mostly found in front teeth area.
- C. double-formations are classified into conerescent, fused and geminated teeth.
- D. double-formations in the primary dentition may be followed by aplasia of the permanent successor.
- E. the fusion of conerescent tooth involves the root cementum, dentin and enamel.

Nr 62. Match the disease name with two parts of its description:

1.	dental fluorosis	a.	a group of inherited defects of dentin formation	I	defects are variable and include abnormalities that are classified as hypoplastic, hypomaturational, and hypocalcification
2.	enamel hypoplasia	b.	a group of inherited defects of enamel formation	II	these conditions can affect only the teeth or can be associated with osteogenesis imperfecta
3.	amelogenesis imperfecta	c.	a condition that results from the intake of too much fluoride during the period of tooth development	III	clinical changes are caused by sub-surface enamel hypomineralisation and porosity
4.	dentinogenesis imperfecta	d.	quantitative defect of enamel	IV	may be hereditary or acquired

A. 1cIV,2dIII,3aI,4bII.

B. 1cI,2bIV,3bIII,4aII.

C. 1cIII,2dIV,3bII,4aI.

D. 1dIII,2bI,3cIV,4aII.

E. 1cIII,2dIV,3bI,4aII.

Nr 63. Which of the following systemic diseases predispose a patient to periodontitis?

A. cyclic neutropenia, insulin dependent diabetes mellitus, Down syndrome.

B. cyclic neutropenia, insulin dependent diabetes mellitus.

C. insulin dependent diabetes mellitus, Down syndrome.

D. insulin dependent diabetes mellitus, Papillon-Lefevre syndrome.

E. cyclic neutropenia, insulin dependent diabetes mellitus, Down syndrome, Papillon-Lefevre syndrome.

Nr 64. The most appropriate treatment following the extraction of a first primary molar in a 4-year-old child is:

A. regular assessment of arch development.

B. the insertion of a space maintainer.

C. the extraction of the contra-lateral molar.

D. the extraction of the opposing molar.

E. the extraction of the permanent successor.

Nr 65. Small, bluish-white macules on a child's buccal mucosa surrounded by a slightly erythematous zone may be seen at the onset of:

A. mumps.

B. scarlet fever.

C. leucemia.

D. measles.

E. rubella.

Nr 66. A 7-year-old child has localized gingival recession on the labial surface of the mandibular incisor (with co-existing crowding of teeth). The **most probable** cause is:

A. labial position of the tooth.

B. mouth breathing.

C. hypophosphatasia.

D. poor eating habits.

E. aggressive periodontitis.

Nr 67. "Strawberry tongue" is an oral manifestation of:

- A. measles. B. scarlet fever. C. varicella. D. rubella. E. mumps.

Nr 68. A 9-year-old boy receives an extended course of tetracycline. Clinical crowns of which of the following teeth are likely to show discoloration?

- A. all permanent teeth. D. the permanent incisors will be discoloured on the incisal edges.
B. no teeth will be discoloured.
C. the premolars. E. the first permanent molars.

Nr 69. Upon oral examination of a child, it is noted that the permanent teeth have been delayed in erupting. Which of the following conditions could cause the delay?

- A. cleidocranial dysostosis, hyperparathyroidism, hyperthyroidism.
B. cleidocranial dysostosis, hypothyroidism, hypopituitarism.
C. osteogenesis imperfecta, hypothyroidism.
D. hyperparathyroidism, hyperthyroidism.
E. hypothyroidism.

Nr 70. Primary mandibular central incisors usually erupt at the months of age:

- A. 6-11. B. 11-20. C. 20-30. D. 30-36. E. 36-48.

Nr 71. The most common cause of generalized acute stomatitis in a preschool child is:

- A. vitamin B deficiency. D. necrotizing ulcerative gingivitis.
B. vitamin C deficiency. E. acute streptococcus mutans gingivostomatitis.
C. herpetic gingivostomatitis.

Nr 72. Which of the following is the most acceptable treatment of a 5-year-old child with a chronically-infected primary molar. X-ray shows presence of the first permanent tooth germ.

- A. treat with antibiotic and allow the tooth to remain in place.
B. allow the tooth to remain in the mouth for a space maintainer.
C. allow the tooth to remain in the mouth unless it is causing pain.
D. extract the tooth.
E. none of the above.

Nr 73. Intrinsic pigmentation of the permanent teeth may be related to:

- A. chronic toxicity of fluoride, idiopathic fibromatosis.
B. chronic toxicity of fluoride, tetracycline therapy.
C. idiopathic fibromatosis, tetracycline therapy.
D. idiopathic fibromatosis, ingestion of iron supplement in vitamin tablets.
E. chronic toxicity of fluoride, idiopathic fibromatosis, tetracycline therapy, ingestion of iron supplement in vitamin tablets.

Nr 74. The most frequent complication of tooth replantation is:

- A. root canal obliteration.
- B. arrest of root formation.
- C. pulp necrosis.
- D. resorption.
- E. none of the above.

Nr 75. A large carious lesion occurs on a permanent first molar of a 7-year-old child. The tooth is vital and symptomless. The X-ray did not reveal periapical involvement. During cavity preparation the pulp was exposed. The treatment should:

- A. cap the exposure with calcium hydroxide and place zinc-oxide and eugenol.
- B. perform a pulpotomy and place calcium hydroxide.
- C. perform a pulpectomy.
- D. extract the tooth and place a space maintainer.
- E. cap the exposure with calcium hydroxide and fill the lesion with glass ionomer cement.

Nr 76. Which of the following **is not** a risk factor for dental caries?

- A. a high *Lactobacillus* count.
- B. a high *Streptococcus mutans* count.
- C. poor oral hygiene.
- D. saliva with high buffering capacity.
- E. a decreased saliva flow rate.

Nr 77. Upon oral examination of a 2-year-old child suffering from a traumatic injury, it is noted that the maxillary central incisors show mobility without displacement. The recommended treatment is:

- A. taking radiographs, repositioning the teeth.
- B. taking radiographs, repositioning the teeth, splinting the teeth, appointing the patient for the recall in one month.
- C. taking radiographs, appointing the patient for the recall in one month.
- D. splinting the teeth, appointing the patient for the recall in one month.
- E. taking radiographs, splinting the teeth.

Nr 78. Dental problems of a child with acute leucemia are characterized by unusual susceptibility to:

- A. dental caries.
- B. oral infection.
- C. bone loss.
- D. the development of jaw deformities.
- E. none of the above.

Nr 79. Oral examination of 4-year-old child showed large cavities in the upper incisors. Permanent restoration should be carried out using:

- A. glass-ionomer or steel crown.
- B. steel crown or composite.
- C. composite or glass-ionomer.
- D. amalgam or phosphate cement.
- E. phosphate cement or steel crown.

Nr 80. Fissure sealing is the method of caries prophylaxis in the following cases **except**:

- A. prevention of caries in pits and fissures.
- B. prevention of caries in milk teeth.
- C. prevention of caries in permanent teeth.
- D. prevention of caries in adults.
- E. prevention of caries of smooth surfaces.

Nr 81. The material which can be used for fissure sealing **is not**:

- A. flow composite.
- B. glass-ionomer cement.
- C. composite.
- D. amalgam.
- E. compomer.

Nr 82. After enucleation and histopathologic examination of a primordial cyst, it is essential to:

- 1) surgically revise the wound and curette the surface of the bone;
- 2) perform follow-up examinations and X-rays;
- 3) microscopically evaluate completion of the procedure;
- 4) administer antibiotics;
- 5) use osteogenic materials to prevent a bone fracture in the enucleation site.

The correct answer is:

- A. 1,3.
- B. 2,3.
- C. 3,4.
- D. 3,5.
- E. 2,5.

Nr 83. Indicate the false sentence concerning the Gorlin syndrome:

- A. it is also known as naevoid basal cell carcinoma syndrome.
- B. it is characterized by skin lesions and bone anomalies.
- C. it is inherited as an autosomal dominant trait.
- D. it is characterized by the occurrence of single cysts.
- E. its histopathologic structure is similar to keratocyst.

Nr 84. The Crile`s method requires removal of:

- A. unilateral suprahyoid nodes together with the contents of the submandibular fossa.
- B. bilateral suprahyoid nodes together with the contents of submandibullar fossae.
- C. unilateral suprahyoid nodes and the internal jugular vein, deep cervical nodes and their surroundings.
- D. unilateral supraclavicular nodes and the external jugular vein, superficial cervical nodes and their surroundings.
- E. unilateral suprahyoid nodes, the internal and external jugular vein, superficial and deep cervical nodes along with the contents of the supraclavicular fossa.

Nr 85. The odontogenic abscess of parapharyngeal space needs to be differentiated from the tonsil-like abscess of this space. The differentiating symptom is:

- A. strong idiopathic pain.
- B. difficulties in eating.
- C. trismus.
- D. high body temperature.
- E. On the basis of clinical examination the differentiation is impossible.

Nr 86. The extraction of 26 tooth caused an oro-antral communication. The symptom of an existing polyp is:

- A. profuse discharge of purulent contents.
- B. discharge of opalescent straw-coloured liquid.
- C. rhinorrhoea while trying to rinse the sinus through the alveolus.
- D. negative nose-blowing test.
- E. resistance to examining the alveolus with a periapical curette.

Nr 87. Diagnosed condition of T1N1M0 of tongue carcinoma requires the removal of:

- A. tumour with a healthy tissue margin.
- B. the tumour with a healthy tissue margin and ipsilateral suprahyoid nodes.
- C. the tumour with a healthy tissue margin, the ipsilateral lymphatic system of the neck and contralateral suprahyoid nodes.
- D. half of the tongue with a part of the floor of the mouth, mandible resection, the removal of the ipsilateral lymphatic system of the neck and contralateral suprahyoid nodes.
- E. half of the tongue along with a part of the floor of the mouth, mandible resection, and the bilateral removal of the lymphatic system of the neck.

Nr 88. Diagnosed condition T2N2M0 of the carcinoma of the floor of the mouth is:

- A. a tumour 2cm or less in maximum dimension, ipsilateral lymph nodes enlarged, mobile, no metastases.
- B. a tumour 2cm or less in maximum dimension, bilateral lymph nodes enlarged, mobile, no metastases.
- C. a tumour more than 2cm in maximum dimension, ipsilateral lymph nodes enlarged, mobile, no metastases.
- D. a tumour more than 2cm in maximum dimension, bilateral lymph nodes enlarged, mobile, no distant metastases.
- E. a tumour more than 2cm in maximum dimension, ipsilateral lymph nodes enlarged, non-mobile, no distant metastases.

Nr 89. The early complications after local anaesthesia include:

- 1) facial nerve paralysis;
- 2) causing the local ischaemia of the skin of the face.
- 3) puncturing the nerve;
- 4) injuring the muscles;
- 5) insufficient anaesthesia.

The correct answer is:

- A. 1,3.
- B. 1,2,3.
- C. 2,4,5.
- D. 3,5.
- E. all the above.

Nr 90. Indicate the **false** sentence: Lidocaine is characterised by:

- A. the time of activity up to about 45 minutes.
- B. the average strength of activity.
- C. no influence on blood vessels.
- D. its use in treating ventricular arrhythmia.
- E. its maximum safe dose of 7 mg per kg.

Nr 91. The epithelial developmental odontogenic cysts **do not** include a/an:

- A. keratocyst.
- B. lateral periodontal cyst.
- C. radicular cyst.
- D. eruption cyst.
- E. dentigerous cyst.

Nr 92. Indicate the **false** sentence concerning Sjorgen`s syndrome:

- A. it's a disease causing damage to parenchyma of endocrine glands by formation of histiocyte infiltrations.
- B. its most common symptom is xerostomia.
- C. it may be associated with systemic lupus erythematosus, scleroderma, hepatic cirrhosis, rheumatic fever.
- D. it shows a female predilection.
- E. the disease can be associated with chronic interstitial nephritis.

Nr 93. Indicate the features that characterize buccal abscess:

- 1) it can be located intra or extra orally, its boundary is the buccinator muscle;
- 2) the abscess occurs often in the buccal space with the following borders: anterior – levator anguli oris muscle; posterior – masseter muscle; roof – zygomatic arch; floor – rim of the mandible;
- 3) buccal abscess is always incised intra-orally because of aesthetical reasons;
- 4) the extraction of the causal tooth is always an inseparable procedure accompanying incision of the abscess and should always be performed during the first visit;
- 5) the cause of the abscess is always an odontogenic infection from the upper molars and premolars.

The correct answer is:

- A. 1,2. B. 3,4. C. 2,3. D. 4,5. E. 1,4.

Nr 94. Indicate the true sentence concerning sarcoidosis:

- A. in oral cavity sarcoidosis occurs as white-bluish nodules located on palatine arches, uvula, along the palatine raphe, and predominantly on the mucosa of the buccae.
- B. granulomatous infiltration present in partoid parenchyma does not cause the paralysis or paresis of the facial nerve.
- C. Hereford and Mikulicz syndrome takes the form of sarcoidosis.
- D. the treatment includes antituberculous drugs and steroids. Immunosuppression is contraindicated because of the origin of the disease.
- E. sometimes additional radiotherapy in doses around 30Gy is indicated.

Nr 95. Odontogenic lesions include (indicate the **false** sentence):

- A. ameloblastoma, ameloblastofibroma, complex and mixed dentinoma.
- B. myxoma, fibromyxoma, chondromyxoma.
- C. gigantiform and ossifying cementoma.
- D. ameloblastic fibrosarcoma, ameloblastic odontosarcoma.
- E. malignant ameloblastoma.

Nr 96. The retromandibular space contains the nerves:

- | | |
|-------------------|----------------------------|
| 1) vagus nerve; | 4) auriculotemporal nerve; |
| 2) facial nerve; | 5) glossopharyngeal nerve. |
| 3) lingual nerve; | |

The correct answer is:

- A.** 1,2,4. **B.** 2,4. **C.** 2,4,5. **D.** 2,3. **E.** 1,5.

Nr 97. Indicate the **false** sentences:

- 1) during a sinus lift procedure it is possible to cause injury to the sinus membrane;
- 2) autogenous bone mixed with bone substitute is recommended for performing a sinus lift;
- 3) performing simultaneously implant placement and augmentation is possible if the alveolar height is at least 2 mm;
- 4) indirect sinus lift allows to rise the sinus floor up to 1-3 cm;
- 5) chronic sinusitis is not regarded as a contraindication for sinus lift.

The correct answer is:

- A.** 1,3. **B.** 3,5. **C.** 2,4. **D.** 1,2. **E.** 4,5.

Nr 98. Indicate the **false** sentences:

- A.** autogenic graft – the donor and recipient are identical.
B. isograft – the donor and recipient are genetically identical.
C. allograft – the donor and recipient are genetically different but belong to the same species.
D. xenograft – the donor and recipient belong to different species.
E. alloplastic material – modified material, deprived of antigenic properties, a counterpart to allograft.

Nr 99. An incorrect technique of performing one of the intraoral conduction anaesthesias, may result in temporary paresis of the facial nerve of this side. This may happen as a result of a block of which of the undermentioned nerves?

- | | |
|------------------------------------|---|
| A. nasopalatine nerve. | D. posterior superior alveolar nerves. |
| B. inferior alveolar nerve. | E. mental nerve. |
| C. infra-orbital nerve. | |

Nr 100. Which of the undermentioned intra-oral abscesses is most probable to cause intracranial complications?

- A.** abscess of the palate.
B. abscess of the canine fossa.
C. abscess in the region of upper premolars on the vestibular side.
D. abscess of the pterygo-palatinal space.
E. correct are B and D.

**Now, take the other answer ticket in order to mark the answers
to questions 101 - 200.**

Nr 101. Which of the undermentioned abscesses, because of its localization, mostly threatens to cause respiratory failure?

- A. palatal abscess.
- B. submasseter abscess.
- C. abscess of the floor of the oral cavity.
- D. lingual abscess.
- E. C and D.

Nr 102. Which of the undermentioned clinical symptoms is most distinctive of submasseter abscess?

- A. oedema and difficulties in swallowing.
- B. very strong pain.
- C. high fever.
- D. trismus.
- E. B and D.

Nr 103. Which of the undermentioned elevators is **most often** used for extracting a tooth or its roots?

- A. Winter`s elevator.
- B. Schlemmer`s elevator.
- C. Bein`s elevator.
- D. Leclus`s elevator.
- E. Berten`s elevator.

Nr 104. In the patients belonging to a high risk group of endocarditis, it is recommended to use antibiotic prophylaxis when performing a dental procedure is, that produces bleeding in the oral cavity. Which of the undermentioned antibiotics should be administered?

- A. erythromycin.
- B. amoxicillin.
- C. ciprofloxacin.
- D. clindamycin.
- E. amoxicillin, and in case of an allergy – clindamycin.

Nr 105. Which of the undermentioned lesions of oral mucosa undergoes most frequently transformation into squamous cell carcinoma?

- A. oral lichen planus.
- B. melanoplakia.
- C. homogenous leukoplakia.
- D. non homogenous leukoplakia.
- E. erythroplakia.

Nr 106. Salivary gland tumours occur commonly in the parotid gland. Which of the undermentioned tumours occurs **most frequently**?

- A. basal cell carcinoma.
- B. Warthin`s tumour.
- C. pleomorphic adenoma.
- D. Stewart`s tumour.
- E. oncocytoma.

Nr 107. How to interpret the following findings in clinical examination of periodontal tissues: 7mm deep pocket and 9mm loss of clinical attachment.

- A. drug related hypertrophic gingivitis is present.
- B. gingival recession equals to 2 mm.
- C. such difference indicates the presence of periodontal abscess.
- D. the hypertrophy in gingivitis is 4 mm.
- E. mild chronic periodontitis in the elderly.

Nr 108. What differentiates chronic and aggressive form of periodontitis?

- A. the periodontal pocket depth.
- B. the X-ray picture.
- C. the average value of the modified bleeding index (mSBI).
- D. a familiar incidence and the rapid CAL loss.
- E. the age of the patient.

Nr 109. In which of the following dermatologic diseases desquamative gingivitis can be observed?

- A. atopic dermatitis.
- B. lichen planus.
- C. psoriasis.
- D. simple acne.
- E. scleroderma.

Nr 110. What is a certain criterion differentiating gingivitis from periodontitis?

- A. the average value of API acc. to Lange et al.
- B. the average value of GI acc. to Loe and Silness.
- C. the presence of periodontal pockets.
- D. the presence of general symptoms.
- E. the coexistence of malocclusion.

Nr 111. What type of periodontal lesions can't be seen in an x-ray picture?

- A. the osteolysis of interdental alveolar bony septum.
- B. over 40% mandibular bone mass loss in osteoporosis.
- C. bone pockets.
- D. furcation defects in mandible.
- E. Miller's class I or class II periodontal recessions.

Nr 112. What should the dentist do in case of a single periodontal abscess in a generally healthy patient?

- A. decompression by incising the abscess.
- B. prescribe erythromycin – 600 mg for 7 days.
- C. extract the tooth next to the periodontal abscess.
- D. decompress the abscess by tooth trepanation.
- E. "intrapocket" irrigation with 12% chlorhexidine solution.

Nr 113. What is the best application of ultrasonic scalers with carbon-fiber reinforced plastic working tips?

- A. supragingival scaling.
- B. tooth polishing.
- C. scaling in periimplantitis.
- D. curettage.
- E. root planing.

Nr 114. Which sentence concerning the application of piezoelectric ultrasonic scalers in subgingival scaling is false?

- A. the working end should contact the tooth at the 80° angle.
- B. water cooling is necessary, and it also enables the cavitation effect.
- C. it saves time compared to hand scalers.
- D. the vibrations of the working end are linear.
- E. it enables the bacteria and their toxins elimination with cement and dentine preservation.

Nr 115. Which of the undermentioned procedures **is not** the element of full mouth disinfection treatment?

- A. subgingival scaling and root planing in 24 hours.
- B. mouth and throat rinsing with chlorhexidine.
- C. the application of chlorhexidine ointment on the dorsal tongue surface.
- D. filling the deepest pockets after scaling with 25% metronidazole.
- E. simultaneous scaling and pocket rinsing with chlorhexidine solution.

Nr 116. In order to perform the scaling of mesial surfaces of the posterior teeth the following Gracey curette is used:

- A. 1/2.
- B. 5/6.
- C. 7/8.
- D. 11/12.
- E. 13/14.

Nr 117. Which of the listed clinical situations is an indication to perform guided tissue regeneration?

- A. a supraalveolar pocket.
- B. an infraalveolar pocket.
- C. a mandibular class III furcation defect acc. to Hamp.
- D. class IV periodontal recession acc. to Miller.
- E. the loss of gingival papillas.

Nr 118. When a periodontal probe passes through the intraradicular space it is named:

- A. a class II furcation defect acc. Hamp.
- B. a class III furcation defect acc. Hamp.
- C. a three wall osseous defect.
- D. Stillman's cleft.
- E. an intraradicular crater.

Nr 119. Which of the undermentioned treatment methods in the maintenance phase causes a significant reduction of periodontopathogens and concentration of proinflammatory mediators in crevicular fluid?

- A. mouth rinsing with 0.12% chlorehexidine solution.
- B. supragingival scaling.
- C. laser biostimulation.
- D. subgingival water irrigations.
- E. the intraoral application of coenzyme Q.

Nr 120. The periotest is used to measure:

- A. teeth mobility.
- B. pocket depth and connective tissue attachment loss.
- C. the intensity of gingival inflammation.
- D. the volume of gingival fluid.
- E. the presence of premature occlusion contacts.

Nr 121. The analysis of the facial profile is carried out in relation to:

- 1) the inter – pupillary lines;
- 2) Simon's orbital plane;
- 3) Kantorowicz's frontal plane;
- 4) the way in which the first permanent molars contact one another;
- 5) the maximal width of the cranium.

The correct answer is:

- A.** 1,5. **B.** 2,3. **C.** 1,3. **D.** 4,1. **E.** 4,2.

Nr 122. A mature swallowing type is indicated by:

- 1) the tongue position in relation to dental arches;
- 2) the contraction of the mylohyoid muscle;
- 3) the hypertonia of the labial and buccal muscles;
- 4) the fact that the air is freely held in the oral cavity;
- 5) the fact that the tongue touches the mentum as well as both cheeks.

The correct answer is:

- A.** 1,2. **B.** 5,3. **C.** 4,1. **D.** 2,3. **E.** 5,4.

Nr 123. The analysis of diagnostic models articulated in a habitual occlusion consists of:

- 1) the assessment of the conformance of both dental arches' midlines;
- 2) the measurement of the width between first upper premolars;
- 3) the analysis of Angle's classes;
- 4) the measurement of the dental arch length;
- 5) the measurement of the dental arch posterior width.

The correct answer is:

- A.** 2,1. **B.** 1,3. **C.** 1,4. **D.** 3,4. **E.** 4,1.

Nr 124. Myotherapy is a prime choice method in treating:

- A.** deep bites.
B. the functional forms of mandibular retropositions.
C. congenital malocclusions.
D. malocclusion in the retention phase after a block appliance.
E. overcrowding of the lower incisors.

Nr 125. The characteristic feature of distocclusion is:

- A.** an excessive width of the maxilla.
B. an underdevelopment of the mandible in all three dimensions.
C. an increased overjet between upper and lower incisors.
D. an asymmetry of the face.
E. retroposition of the upper lip.

Nr 126. A lateral cephalometric radiogram is used as:

- A. an additional examination in orthodontic diagnostics.
- B. a general examination in functional disorders of the temporomandibular joint.
- C. a method of detecting carious lesions.
- D. a method of assessing the periodontal condition.
- E. a method of assessing teeth development.

Nr 127. The features of retrognathia are:

- 1) an inhibition of the frontal development of the maxilla;
- 2) an asymmetry of the face;
- 3) the smoothing of the labiomental sulcus;
- 4) lingual occlusion;
- 5) an increase in the facial width between the mandibular angles.

The correct answer is:

- A. 4,2. B. 1,2. C. 4,1. D. 5,3. E. 1,3.

Nr 128. The counter-clockwise growth of the facial cranium indicates:

- A. faster growth of the anterior height of the facial cranium in relation to the posterior one.
- B. anteroposterior relations of the apical bases of the maxilla and the mandible.
- C. faster growth of the posterior height of the facial cranium in relation to the anterior one.
- D. the growth of the facial cranium downwards and backwards.
- E. the same rate of the growth of the anterior and the posterior facial height.

Nr 129. The key features of the mandibular prognathism are:

- 1) the prominence or protrusion of the upper dental arch;
- 2) in deciduous dentition – the final plane broken to the back;
- 3) a forward position of the mentum in relation to the biometric field;
- 4) the shortening of the maxillary segment of the face in relation to the nasal segment;
- 5) the smoothing of the labiomental sulcus.

Correct answer:

- A. 1,5. B. 2,4. C. 3,5. D. 4,3. E. 4,5.

Nr 130. The disorders of the development and functions of the masticatory system caused by a premature loss of deciduous teeth may appear as:

- 1) an improper performance of physiological activities;
- 2) an inhibition of bone growth in an after tooth extraction place;
- 3) an increase in the carious process;
- 4) asymmetric mandibular prognathism;
- 5) breathing with an open mouth.

The correct answer is:

- A. 1,5. B. 2,1. C. 3,5. D. 4,3. E. 4,2.

Nr 131. During infancy the position of the mandible to the maxilla in relation to the sagittal plane is assessed on the basis of:

- A. the position of the upper lip frenulum in relation to the sagittal plane.
- B. the position of the incisive papilla.
- C. the mutual positions of both frenula in relation to the orbital plane.
- D. the position of the torus palatinus.
- E. the mutual positions of the mandibular frenula in relation to the maxillary ones.

Nr 132. The occlusal norm of the early full deciduous dentition is settled:

- A. after the eruption of the first deciduous molars.
- B. after the eruption of the lower deciduous canines.
- C. after the eruption of the deciduous canines and the second molars.
- D. during the twentieth month of life.
- E. when the first deciduous molars reach the occlusal plane.

Nr 133. An infant improperly fed with a baby bottle may develop:

- A. a shift of the mandible and the tongue to the front.
- B. scoliosis.
- C. a narrow maxilla.
- D. asymmetric mandibular prognathism.
- E. an exudative defect.

Nr 134. The sucking reflex disappears after:

- A. the first year of age.
- B. the sixth month of age.
- C. the 18th month of age.
- D. between the 8th and 10th month of age.
- E. the 40th month of age.

Nr 135. A standard vestibular plate is an appliance used for:

- 1) eliminating oral habits;
- 2) treating deep bites;
- 3) treating lingual occlusion;
- 4) treating distocclusion complicated by the protrusion of the upper incisors;
- 5) treating mesiocclusions.

The correct answer is:

- A. 1,4.
- B. 5,2.
- C. 3,5.
- D. 3,4.
- E. 2,3.

Nr 136. A characteristic feature of Hotz and Nord's vestibular plate is:

- A. that its edge touches the demarcation line between movable and fixed mucosa.
- B. that its activation is impossible.
- C. its contact with the alveolar process in the lateral parts.
- D. that in treating distocclusion, taking a constructive bite involves disarticulating the maxilla and the mandible.
- E. taking a constructive bite in such a way that the upper canines are in the space between the canine and the first lower deciduous molar and the occlusion is raised over the size of the rest gap.

Nr 137. Delayed tooth eruption or tooth retention usually concerns:

- 1) upper central incisors;
- 2) lateral lower incisors;
- 3) first permanent molars;
- 4) second upper premolars;
- 5) canines.

The correct answer is:

- A.** 1,5. **B.** 3,4. **C.** 1,2. **D.** 5,2. **E.** 2,3.

Nr 138. During the period of deciduous dentition vertical disorders treatment planning should take into account:

- 1) the moving of the mandible to the front;
- 2) the elongation of the shortened alveolar processes together with the teeth in lateral parts;
- 3) achieving Angle's first class;
- 4) the expansion of the upper dental arch;
- 5) lowering the alveolar processes in the regions of contacting teeth.

The correct answer is:

- A.** 1,5. **B.** 3,4. **C.** 2,5. **D.** 3,5. **E.** 4,5.

Nr 139. In treating full mesiocclusion one ought to:

- A.** elongate alveolar processes of the maxilla in lateral parts.
B. align dental arches in Angle's second class.
C. protrude upper incisors.
D. move the lower dental arch to the back.
E. retrude the lower incisors.

Nr 140. In orthodontic practice tooth extraction may be performed in case of:

- A.** deep bites treatment. **D.** cosmetic indications.
B. the lack of space below 4 millimetres. **E.** oligodontia.
C. a forward position of both lips in relation to the aesthetic line.

Nr 141. Extensive abrasion can result in:

- A.** stomatitis prothetica. **D.** dentitio difficilis dentis sapientiae.
B. caries florida. **E.** occlusal vertical dimension decrease.
C. a fracture of mandible.

Nr 142. Which of the undermentioned factors **is not** thought to be the cause of tooth wear?

- A.** parafunctions.
B. bruxism.
C. nutritional customs: the consumption of acid and coarse-grained food.
D. smoking.
E. increased psychoemotional tension.

Nr 143. Tooth wear together with paradonthopathy and mioartropathy are reckoned in:

- A. orthognathic bite.
- B. eugnathic bite.
- C. traumatic bite.
- D. cross bite.
- E. edge-to-edge bite.

Nr 144. Oral habits involving of involuntary rhythmic or spasmodic non-functional gnashing, grinding, or clenching of teeth leading to tooth abrasion is defined as:

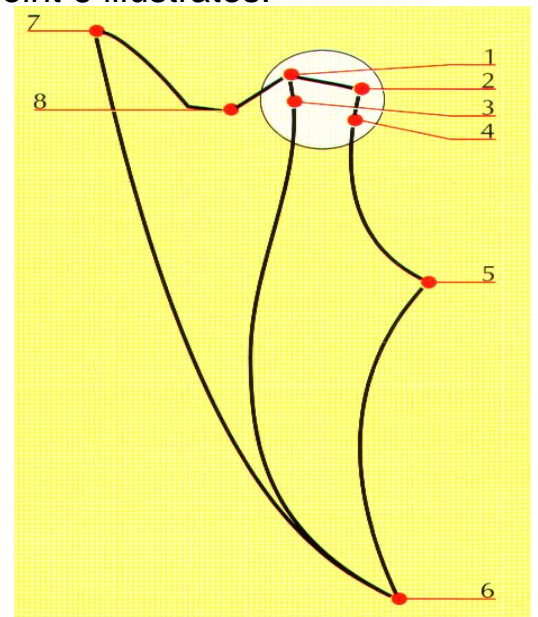
- A. Christensen phenomenon.
- B. biocompatibility.
- C. biomechanics.
- D. bruksism.
- E. decubitus.

Nr 145. A synonym for fully adjustable, individual articulators is:

- A. hinged articulators.
- B. occluders.
- C. simultaneous articulators.
- D. mandible movements simulators.
- E. synchronic articulators.

Nr 146. The schema represents Posselt's diagram. Point 6 illustrates:

- A. maximal mandible protrusion.
- B. mandible rest position.
- C. maximal incuspidation.
- D. the terminal point of hinging mandible motion.
- E. maximal opening.



Nr 147. The presented below impression tray is used for taking:

- A. anatomic impressions.
- B. direct denture lining impressions.
- C. alginate impressions.
- D. functional impressions.
- E. indirect denture lining impressions.



Nr 148. A prosthodontic treatment plan including clasp-retained partial denture demands diagnostic casts analysis by means of:

- A. articulator.
- B. polymerization unit.
- C. periodontometer.
- D. apex locator.
- E. dental surveyor (Ney paralelometer).

Nr 149. Which of the below listed impression materials is **contraindicated** for taking impressions for a master cast in order to prepare clasp-retained partial denture?

- A. agar.
- B. polyether.
- C. silicone.
- D. alginate.
- E. zinc oxide-eugenol paste.

Nr 150. Mesio-occlusal rest in clasp-retained partial dentures is recommended for:

- A. a bilateral distal extension.
- B. a unilateral distal extension.
- C. a unilateral tooth supported.
- D. a edentulous jaw.
- E. is not recommended in clasp-retained partial dentures.

Nr 151. Which of the materials used for fixed prosthesis is **the most** biocompatible?

- A. well polymerized and polished acrylic resin.
- B. chromium-nickel steel.
- C. glazed porcelain and gold alloys.
- D. cobalt-molybdenum steel.
- E. protemp.

Nr 152. The functional value of prosthodontic crown is influenced by:

- A. colour.
- B. impression technique.
- C. reestablishing and preserving an individual occlusal pattern.
- D. chamfer preparation technique.
- E. feather edge preparation technique.

Nr 153. Indicate the impression material **not used** for master cast preparation:

- A. impression compound.
- B. alginates.
- C. silicones.
- D. polyesters.
- E. zinc oxide-eugenol paste.

Nr 154. Which test serves the functional border molding of an individual tray?

- A. provocative clenching.
- B. Herbst.
- C. Schüller.
- D. swing.
- E. Eichner.

Nr 155. A dental surveyor (Ney paralelometer) is used to:

- A. evaluate tooth mobility.
- B. determine masseter muscles tension.
- C. determine an occlusal vertical dimension.
- D. determine a rest vertical dimension.
- E. analyze the anatomic form of abutment teeth.

Nr 156. No or incorrect tooth support can lead to:

- A. a poor esthetic result of prosthesis.
- B. extensive protrusion.
- C. denture settling.
- D. hindering the mandibular opening.
- E. galvanic cell formation.

Nr 157. Surveying is recommended:

- A. only during clasp-retained partial denture fabrication.
- B. only during crown fabrication.
- C. for all types of prostheses.
- D. only during cast post and core fabrication.
- E. only during inlay and onlay fabrication.

Nr 158. The factors influencing the gypsum setting are:

- A. chemical, thermal.
- B. chemical, thermal, mechanical.
- C. only chemical.
- D. thermal.
- E. mechanical.

Nr 159. Zinc oxide-eugenol paste is used for:

- A. denture lining impressions.
- B. diagnostic impressions.
- C. the final impressions for fixed dental prosthesis.
- D. functional and denture lining impressions.
- E. functional impressions.

Nr 160. The causative factor for tissue irritation and ulceration in the oral vestibule in patients wearing complete dentures can be:

- A. too extensive denture plate.
- B. rough and sharp denture border.
- C. unbalanced occlusion on the opposite side.
- D. A and B.
- E. A,B and C.

Nr 161. The cause of pronunciation disorders in patients who have just received new complete dentures can be:

- A. occlusal vertical dimension increase.
- B. an inadequate denture plate shape.
- C. insufficient space for tongue.
- D. an improper tooth arrangement.
- E. all answers are correct.

Nr 162. At the check-up a patient who has received new complete dentures complains of a sore throat. The reason for that can be:

- A. too long or too deep distal periphery seal.
- B. too long or too deep disto-inferior border.
- C. occlusal vertical dimension increase.
- D. A and B.
- E. a sore throat can't be related to new dentures.

Nr 163. To replace missing teeth 24 and 26 with bridge one can plan the following bridge constructions:

- A. 23 0 25 0 27.
- B. 23 0 25 0.
- C. 0 25 0.
- D. A & B are correct.
- E. all answers are correct.

Nr 164. To fabricate cast post and core using the direct method after tooth preparation the pattern for casting procedure is made out of:

- A. modeling wax.
- B. casting (inlay) wax.
- C. metal-impregnated waxes.
- D. selfcuring material (for example Duralay).
- E. B & D are correct.

Nr 165. The materials applied after vital tooth preparation should:

- A. be antibacterial and anti-inflammatory.
- B. stimulate pulp to dentine formation.
- C. block dentinal tubules.
- D. A and C.
- E. A,B and C.

Nr 166. The correct position of patient when performing CPR is:

- A. a supine position on a hard floor.
- B. a side-lying position.
- C. a supine position with the legs raised.
- D. the position depends on the cause of the circulatory failure.
- E. all answers are correct.

Nr 167. During advanced life support actions external defibrillation shocks should be performed:

- A. in sequences of 3.
- B. in sequences of 5.
- C. in sequences of 7.
- D. once and immediately return to resuscitation actions.
- E. none of the above.

Nr 168. The drug which is not likely to stop convulsion seizure is:

- A. diazepam.
- B. midazolam.
- C. fenytoin.
- D. remifentanil.
- E. answers A,B and C are correct.

Nr 169. Cardiac tamponade comprises a group of symptoms being a result of pericardial blood, air or effusion which may lead to life hazard as heart muscle compression forms an obstacle for venous flow and diminishes cardiac output.

- A. both statements are true and form casual nexus.
- B. both statements are true but form no casual nexus.
- C. first statement is true and the second one is false.
- D. first statement is false and the second one is true.
- E. both statements are false.

Nr 170. The first action in BLS algorithm is to:

- A. perform 2 rescue breaths.
- B. perform 30 chest compressions.
- C. perform 15 chest compressions.
- D. call emergency service.
- E. make sure whether the victim and all the bystanders are safe.

Nr 171. Shock may be the result of:

- A. oligovolemia.
- B. sudden vasodilatation.
- C. heart pump insufficiency.
- D. adrenergic system stimulation.
- E. answers A,B and C are correct.

Nr 172. The concept of Chain of Survival includes:

- 1) early recognition of the emergency and calling for help;
- 2) early bystander resuscitation;
- 3) early defibrillation;
- 4) early advanced life support and postresuscitation care.

The correct answer is:

- A.** 1,2,4. **B.** 1,3,4. **C.** 2,3,4. **D.** 1,2,3. **E.** all the above-mentioned.

Nr 173. The guidelines of the Polish (European) Resuscitation Committee, dealing with sudden cardiac arrest in adults and basic life support actions, allow following correlation between chest compressions and rescue breaths:

- A.** 30 chest compressions and 2 rescue breaths.
B. 2 chest compressions and 30 rescue breaths.
C. 5 chest compressions and 1 rescue breath.
D. continuous chest compressions with no rescue breaths.
E. answers A and D are both correct.

Nr 174. In case of pulmonary embolism we frequently use:

- A.** dopamine. **B.** dobutamine. **C.** heparine. **D.** nitroglicerine. **E.** only oxygen.

Nr 175. In an anaphylactic reaction:

- A.** symptoms are evoked by histamine liberation.
B. we use antihistaminic drugs as well as steroids.
C. not all of the symptoms of an anaphylactic reaction are present at the same time.
D. in a patient with difficulties in breathing and cyanosis adrenaline should be used.
E. all answers are true.

Nr 176. A dental practitioner has to be additionally trained before starting practicing their profession when:

- A.** he/she has got a limited right to practice and wants to start practicing the profession 5 years after having finished his/her vocational training.
B. he/she has got a limited right to practice and wants to start practicing the profession 1 year after having finished his/her vocational training.
C. he/she does not have to be additionally trained in any situation.
D. he/she stayed and practiced the profession abroad for a 5 years time.
E. he/she stayed and practiced the profession outside the European Union.

Nr 177. The internationally accepted bioethical principles and Polish medical law say that an experiment in dentistry involving people can be conducted only by:

- A.** a professor or an assistant professor.
B. a dental practitioner who is a specialist in an appropriate area of medicine.
C. a pharmacist working in scientific research.
D. a dental practitioner who has appropriate professional and ethical qualifications.
E. a scientist employed by a university.

Nr 178. The medical law and medical ethics principles require from a dental practitioner to:

- A. keep medical secrecy until patient's death.
- B. keep medical secrecy and patient's death does not let them off it.
- C. release the information about the health of the patients serving socially important functions.
- D. release the information about the health of the patients who are public servants.
- E. release the information about the health of minors.

Nr 179. Medical experiments involving persons able to take legal decisions but not able to consciously declare their opinions can be performed by a dental practitioner only after obtaining the consent of:

- A. the council of dental practitioners from his/her clinic.
- B. councils of dental practitioners (at least one of them must be from an outside medical institution).
- C. a legal tutor.
- D. a tutelary court.
- E. the manager of his/her medical institution (after proposing his/her motion).

Nr 180. A person may be compulsory hospitalized in a psychiatric ward when:

- A. such a need is declared by his/her relatives.
- B. such a need is perceived by his/her family physician.
- C. his/her behavior shows that because of his/her health problem he/she directly threatens his/her or somebody else's life or health.
- D. it is directed in an appropriate document by the police.
- E. the law does not regulate the principles of compulsory psychiatric hospitalization.

Nr 181. The abiding and irreversible end of brain activity is unanimously declared (after fulfilling legal criteria) by a committee of:

- A. neurologists.
- B. anesthetists.
- C. physicians of different specialties.
- D. three physicians: internal medicine specialist, anesthetist, neurosurgeon.
- E. three physicians-specialists; at least one anesthetist and one neurologist or neurosurgeon among them.

Nr 182. The basic bioethical and legal principle of the Convention on Human Rights and Biomedicine declares:

- A. primacy of a human being – interest and good of a human being is above exclusive interest of the society or science.
- B. interest of the society enables to omit human rights.
- C. interest of the science in well-founded situations enables to omit the rights of a human being.
- D. a dental practitioner engaged in medical research must be in line with general professional standards.
- E. psychiatric patients and prisoners can be used in medical research when it is justified by an important social interest.

Nr 183. The Polish Medical Code of Ethics (MCE) makes the conscience clause:

- A. unlimited.
- B. limited.
- C. MCE does not regulate this.
- D. MCE ignores dental practitioners conscience.
- E. MCE orders administrative procedure.

Nr 184. What kind of risk is admissible in therapeutic experiments in human?

- A. no risk.
- B. minimal.
- C. positive.
- D. proportional.
- E. relative.

Nr 185. Does the Polish Medical Code of Ethics (MCE) have got any regulation concerning taking bone marrow from children?

- A. it is a hematological not ethical problem.
- B. no.
- C. yes.
- D. MCE forbids it.
- E. MCE quotes the general regulations in force.

Nr 186. A training pension is granted to a person with the required length of the insurance period who has obtained the decision concerning:

- A. partial incapacity to work.
- B. complete incapacity to work.
- C. temporary incapacity to work.
- D. advisability of training for a new occupation because of inability to work in the previous profession.
- E. total incapacity for military service and capacity to work.

Nr 187. In accordance with the Law on social insurance in case of work accidents and occupational diseases the persons who have suffered permanent or long-lasting health damage, and a certifying doctor has issued a statement of the percentage of health damage resulting from a work accident or an occupational disease are entitled to:

- A. a pension because of partial incapacity to work.
- B. a pension because of complete incapacity to work.
- C. a pension because of incapacity for military service.
- D. one and only indemnity.
- E. a pension because of disability.

Nr 188. A pension is paid out from the Pension Fund to an insured person with the required length of contributory and non-contributory period and who has obtained a medical statement concerning:

- A. incapacity to work which occurred within the insurance period but not later than within 18 months from the cessation of the employment.
- B. complete incapacity to do farm work.
- C. complete incapacity for military service.
- D. incapacity to work which occurred within the insurance period but not later than 36 months after the cessation of the employment.
- E. considerable disability.

Nr 189. An agricultural pension is granted to an insured person with the required length of the old age and disability pension insurance period and with a medical statement concerning:

- A. complete incapacity to do farm work which occurred within the insurance period but not later than 24 months after the cessation of the insurance.
- B. moderate disability.
- C. considerable disability.
- D. complete incapacity to do farm work which occurred within the insurance period but not later than 18 months after the cessation of the insurance.
- E. incapacity to work which occurred within the insurance period but not later than 36 months after the cessation of the insurance.

Nr 190. In establishing the entitlement to benefits from the Social Insurance Fund SIF certifying doctors **do not** issue a statement concerning:

- A. incapacity to work – for pension purposes.
- B. the necessity for therapeutic rehabilitation as a method of pension prevention.
- C. permanent or long-lasting health damage caused by a work accident or an occupational disease.
- D. the degree of disability.
- E. the relation between incapacity to work and a work accident or an occupational disease.

Nr 191. A social pension is not granted to an adult who is completely incapable to work because of health damage which occurred:

- A. before reaching the age of 18.
- B. during education a period – school, university – before reaching the age of 25.
- C. during PhD studies.
- D. during post-graduate studies.
- E. during employment.

Nr 192. In accordance with the Law on cash benefits from social insurance in case of sickness and maternity the doctor's statement about temporary incapacity for work because of sickness or a hospital stay contains the statistical number of the disease established in accordance with the following:

- A. The Labour and Social Policy Minister's decree.
- B. The International Classification of Disability.
- C. The International Functional Classification.
- D. The International Statistical Classification of Diseases and Health Problems.
- E. the list of occupational diseases.

Nr 193. The main global processes which exert an effect on health are:

- 1) demographic changes;
- 2) the ecological situation;
- 3) economic development;
- 4) technological progress;
- 5) the increasing sphere of poverty;
- 6) "traditional" and new diseases and health risks;
- 7) increase in human-made disasters and conflicts.

The correct answer is:

A. 1,2,6. **B.** 2,3,4,7. **C.** 1,3,5,6. **D.** 2,5,6,7. **E.** all the above-mentioned.

Nr 194. According to the concept of 'health fields' by M. Lalonde which of the factors mentioned below affects human health to the smallest degree?

- A.** biological/genetic factors. **D.** the organization and functioning of health care.
B. environmental factors. **E.** socio-economic factors.
C. lifestyle.

Nr 195. The strategic goal of the National Health Programme for the years 1996-2005 assumed that the improvement in the state of health and, associated with it, the quality of life of the population may be achieved through the following:

- A.** changing the life style of the population.
B. shaping the environment promoting health conditions.
C. shaping the occupational environment promoting health conditions.
D. decreasing inequalities concerning health and improving access to health services.
E. all the above-mentioned.

Nr 196. The scope of public health activities aiming to protect individuals covers the following:

- 1) the provision of full availability of preventive vaccinations;
- 2) early detection and treatment of contagious diseases, including tuberculosis and AIDS;
- 3) free medical services for selected social/mental diseases, diabetes and addictions;
- 4) screening tests and active counselling for groups at high risk of contracting diseases of social importance;
- 5) provision of medical assistance for the unemployed and homeless.

The correct answer is:

A. only 1. **B.** 2,3. **C.** 1,4,5. **D.** 3,4,5. **E.** all the above-mentioned.

Nr 197. Indicate the **false** answer in the statement: 'Public health is the science'

- A.** medical. **B.** computer. **C.** social. **D.** natural. **E.** empirical.

Nr 198. The first stage prophylaxis covers:

- A. actions directed towards early detection of diseases and their causes.
- B. actions with respect to a disease which has already developed.
- C. actions biased towards strengthening health.
- D. early rehabilitation of people with motor organ diseases.
- E. all the abovementioned.

Nr 199. The base for the methodology of scientific research in public health are:

- A. epidemiological methods.
- B. statistical methods.
- C. demographic methods.
- D. sociological and economic methods.
- E. all the abovementioned.

Nr 200. Which risk factor of ischemic heart disease is associated with the style of life?

- A. low physical activity.
- B. tobacco smoking.
- C. high calorie diet rich in saturated fats and cholesterol.
- D. excessive consumption of alcohol.
- E. all the abovementioned.

Thank you!